



**MEET** 2008  
MULTIDISCIPLINARY EUROPEAN  
ENDOASCULAR THERAPY

[www.meetcongress.com](http://www.meetcongress.com)

# FIRST CASE PATIENT 5

**MAX AMOR**

**GERARD ETHEVENOT, ZUKAI CHATI**

**CLINIQUE LOUIS PASTEUR**

**ESSEY-LES-NANCY , FRANCE**



**MEET** 2008  
MULTIDISCIPLINARY EUROPEAN  
ENDOASCULAR THERAPY

[www.meetcongress.com](http://www.meetcongress.com)

# **RIGHT LIMB SALVAGE WITH MULTILEVEL STENTING**

**MAX AMOR**

**GERARD ETHEVENOT, ZUKAI CHATI**

**CLINIQUE LOUIS PASTEUR**

**ESSEY-LES-NANCY , FRANCE**

# History

- 81years old woman
- Diabetic insulin-dependent
- Stage IV with non healing ulcer
- General signs of infection
- Referred for limb salvage

# Procedure

- 5F Left Femoral Approach
- Global angiography followed by contralateral revascularization
- Multilevel angioplasty and stenting

PARIZOT, MAURICETTE, 06013218, 26/06/1927, F  
Run 1 - Frame 1 / 16

0.192

Clinique Louis Pasteur  
80kV, 30mA  
Zoom 63%

RAD 0,0°  
SAD 2,4°

L 593  
W 593

PARIZOT, MAURICETTE, 06013Z18, 26/06/1927, F  
Run 2 - Frame 1 / 15

Cinique Louis Pasteur  
80kV, 5mA  
Zoom 63%

RAD 0,0°  
L 500

L 500  
V 500

PARIZOT, MAURICETTE, 06013216, 26/06/1927, F-  
Run 3 - Frame 1 / 13

© 192

Clinique Louis Pasteur  
70kV, 84mA  
Zoom 63%

RAO -18,4°  
CAUD -1,4°

L 593  
1918001

PARIZOT, MAURICETTE, 06013216, Z6/06/1927, F  
Run 4 - Frame 1 / 9

1195

Clinique Louis Pasteur  
65kV, 12mA  
Zoom 63%

AO 0,1°  
Capit 0,05°

L 598  
W 600



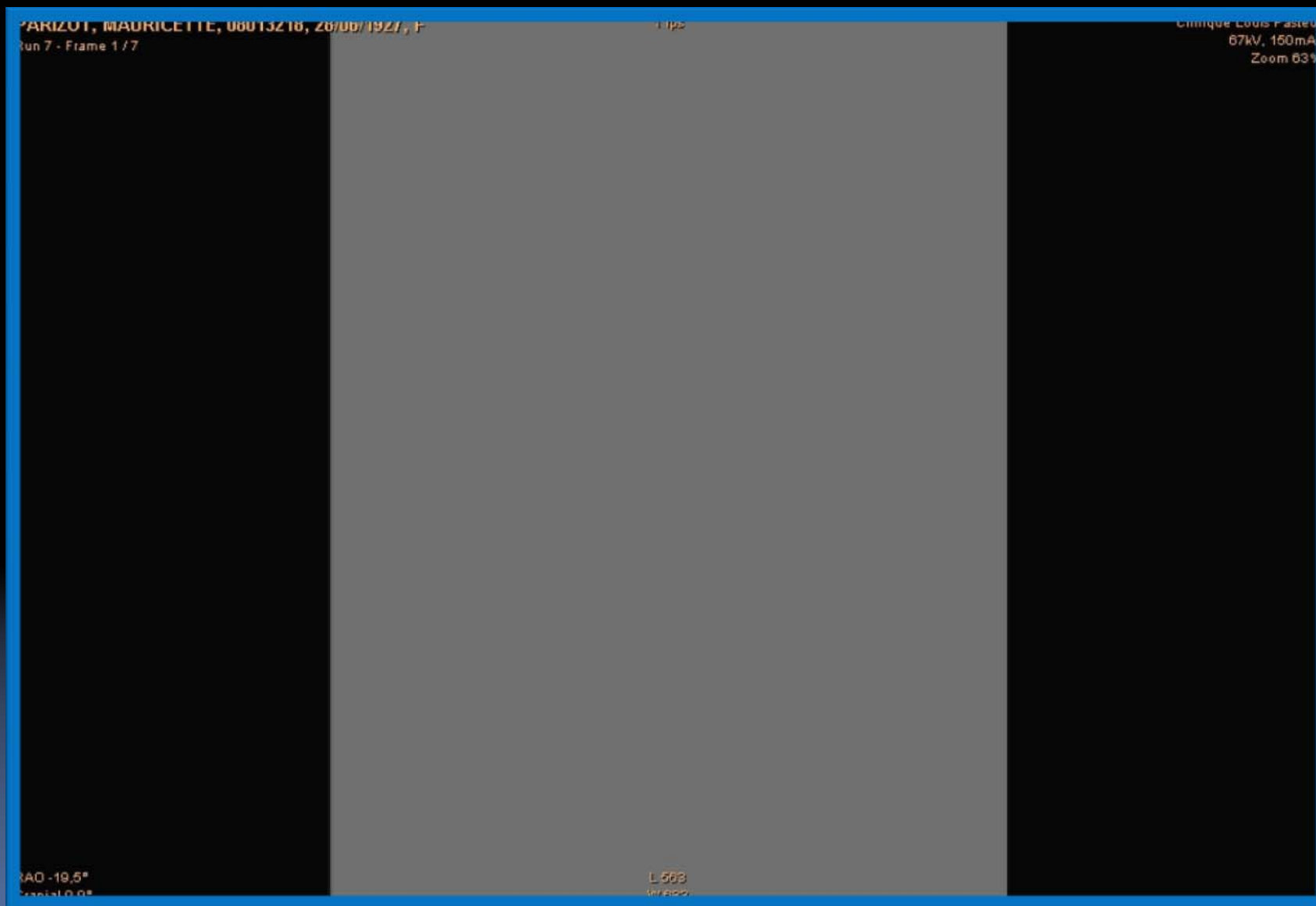
PARIZOT, MAURICETTE, 06013216, 26/06/1927, F-  
Run 5 - Frame 1 / 11

Clinique Louis Pasteur  
65kV, 9mA  
Zoom 63%

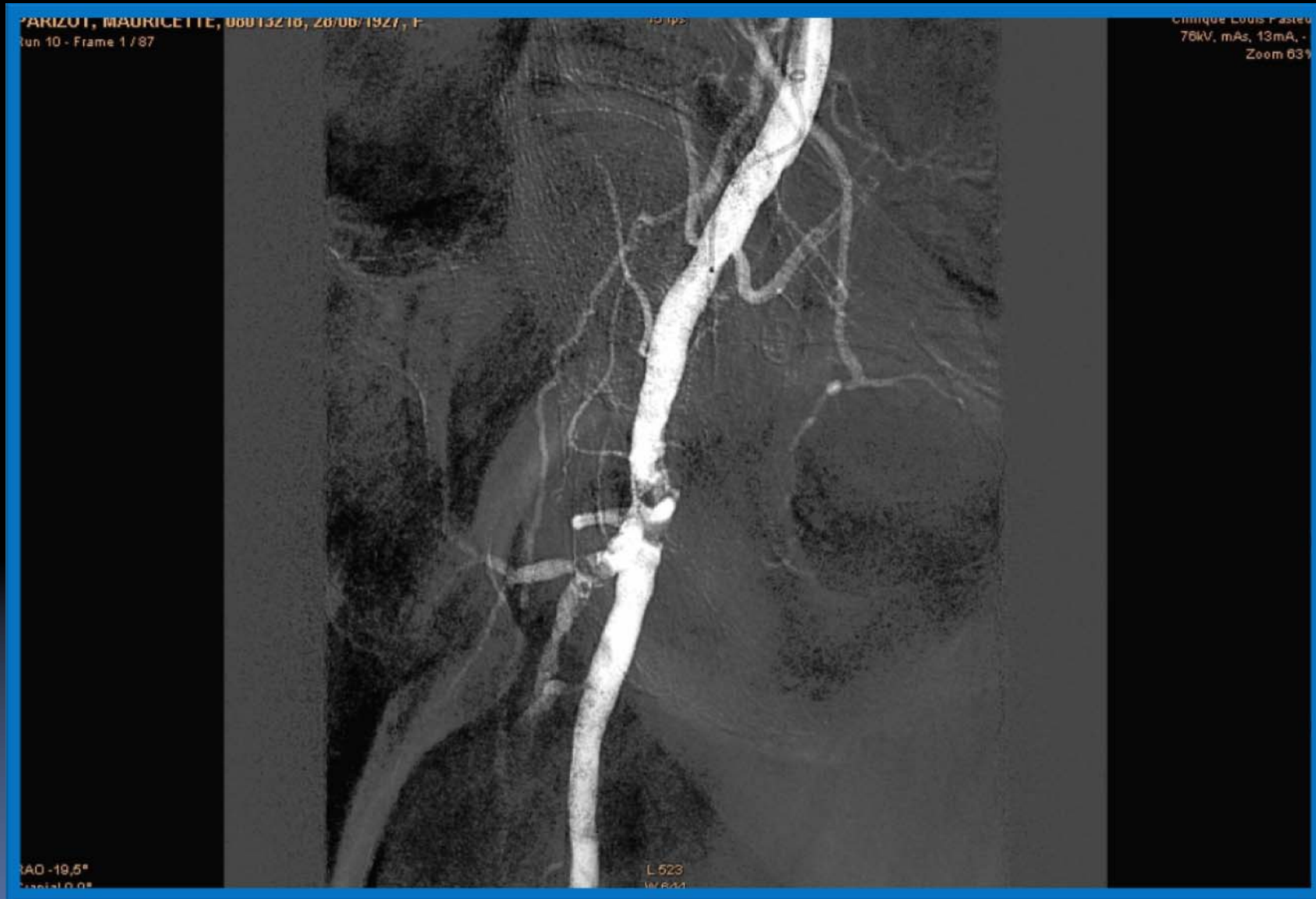AO 0,1°  
Magn 10,0x

L 593  
(M 500)


# Contralateral : 6F 45cm introducer



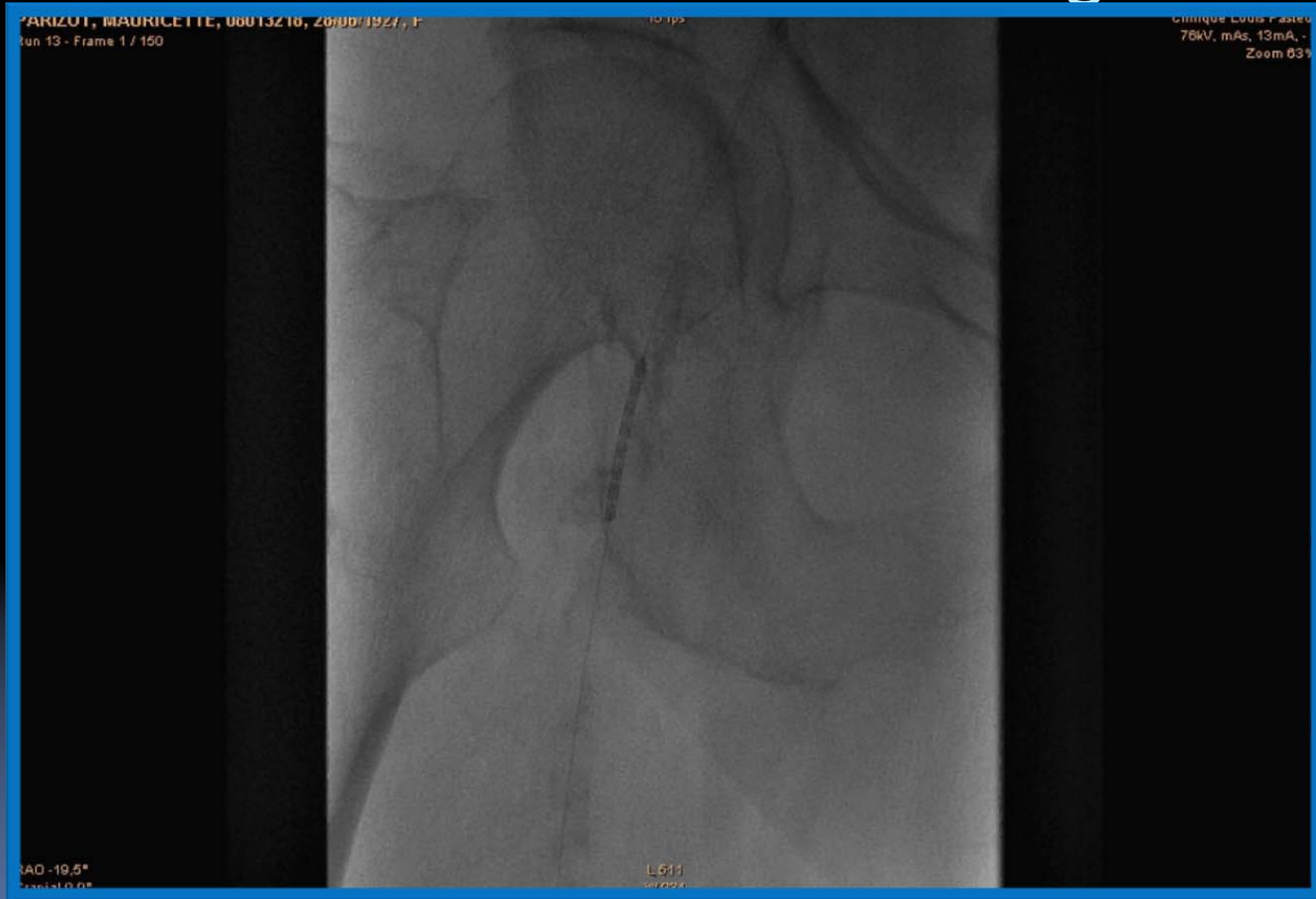
# Abbott 0.014 GW / BSC Maveric



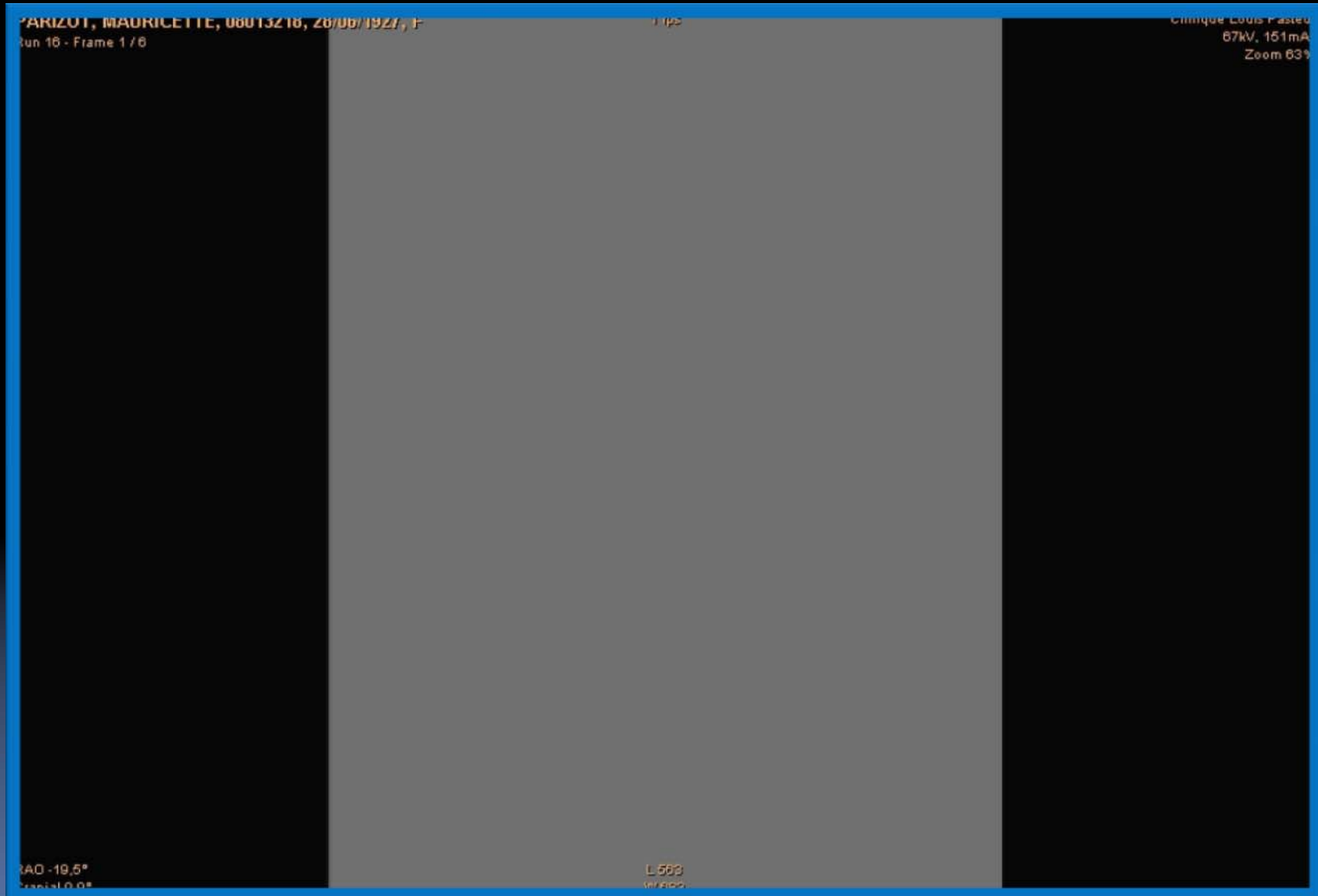
# Stent Palmaz Blue™ Cordis 6x24mm



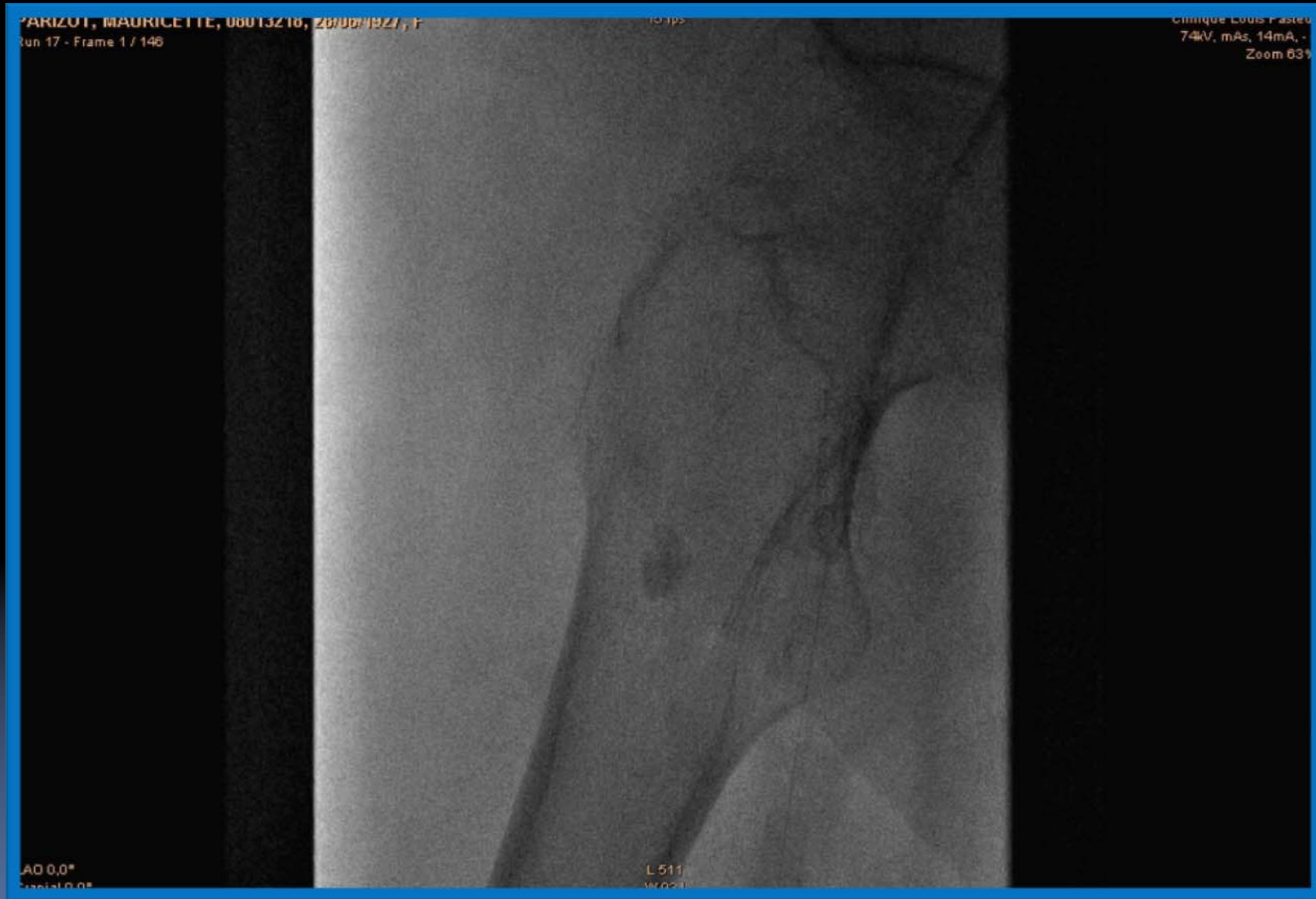
# Common femoral stenting



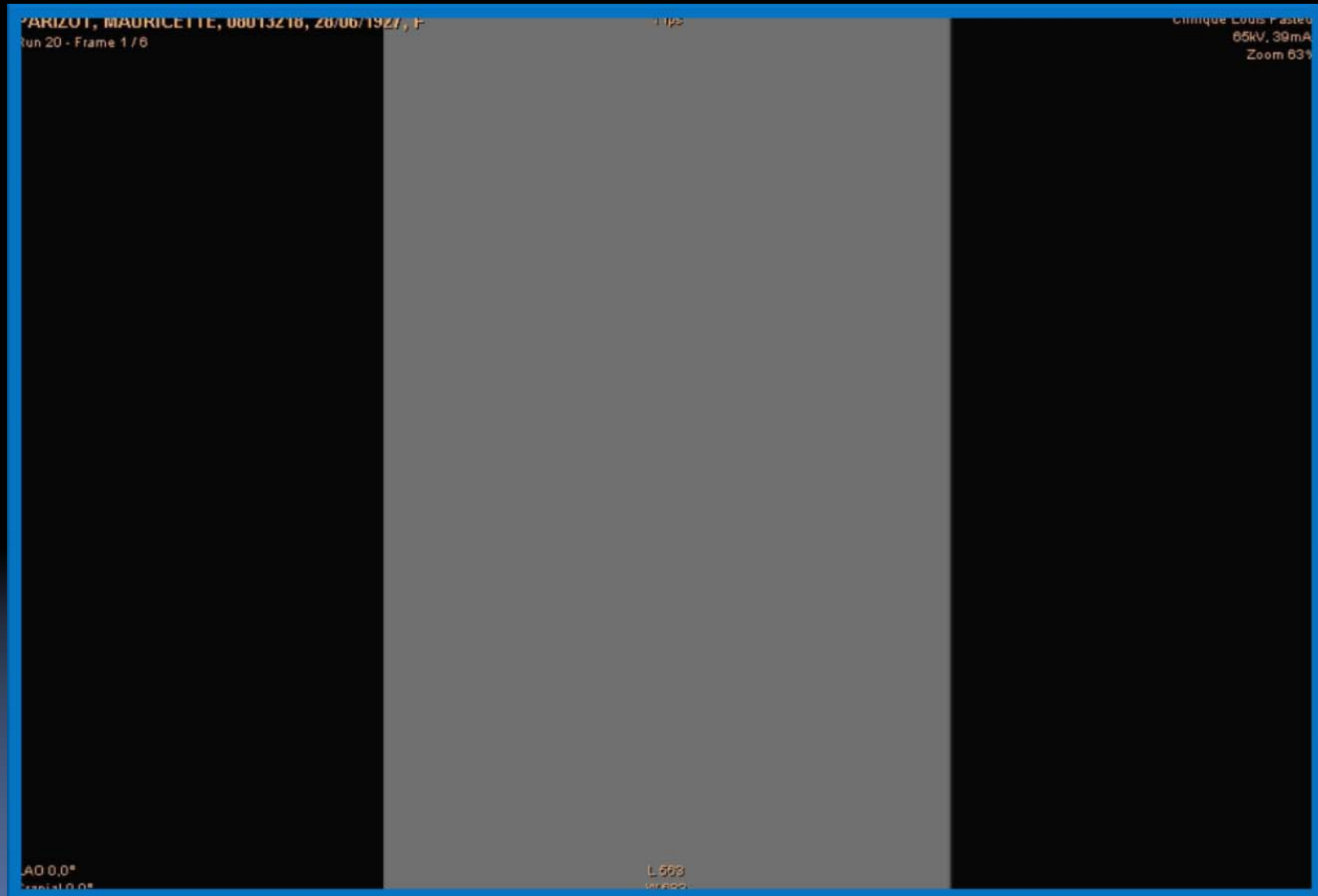
# Result after right common femoral



# Crossing common femoral stent: 4F Terumo straight catheter



# Femoro-popliteal occlusion



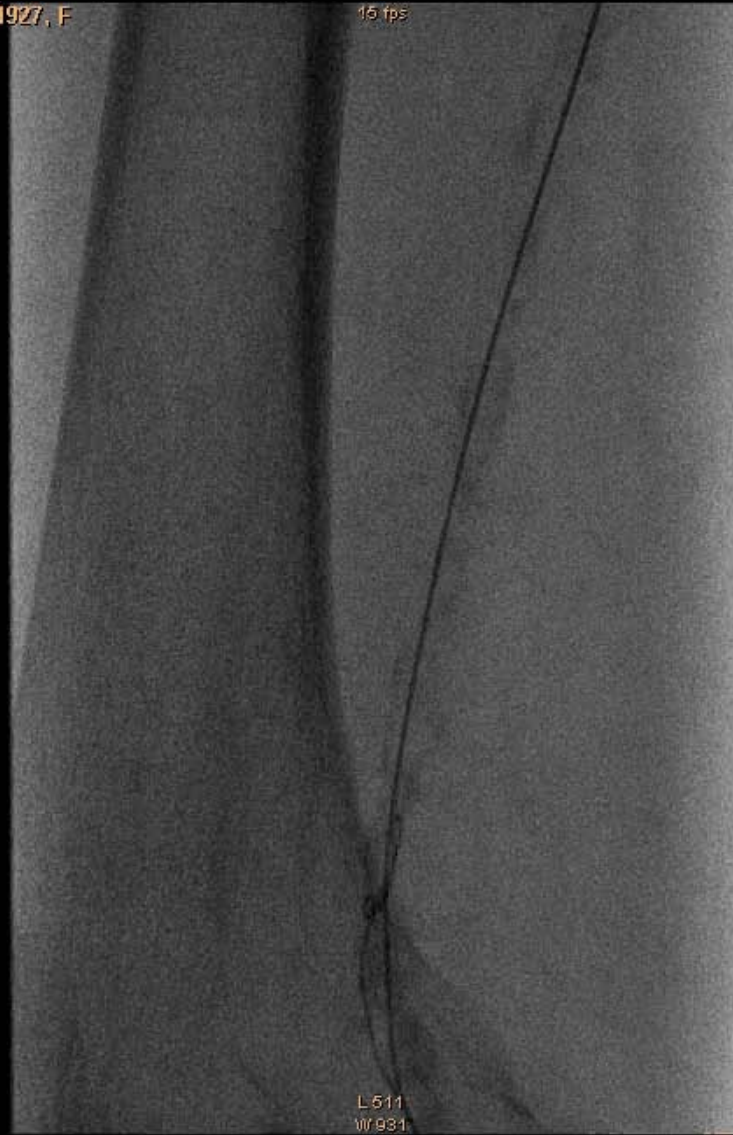


# Subintimal angioplasty . Stop of Terumo GW

PARIZOT, MAURICETTE, 08013218, 28/06/1927, F  
Run 23 - Frame 1 / 134

15 fps

Clinique Louis Pasteur  
63kV, mAs, 9mA, - s  
Zoom 63%

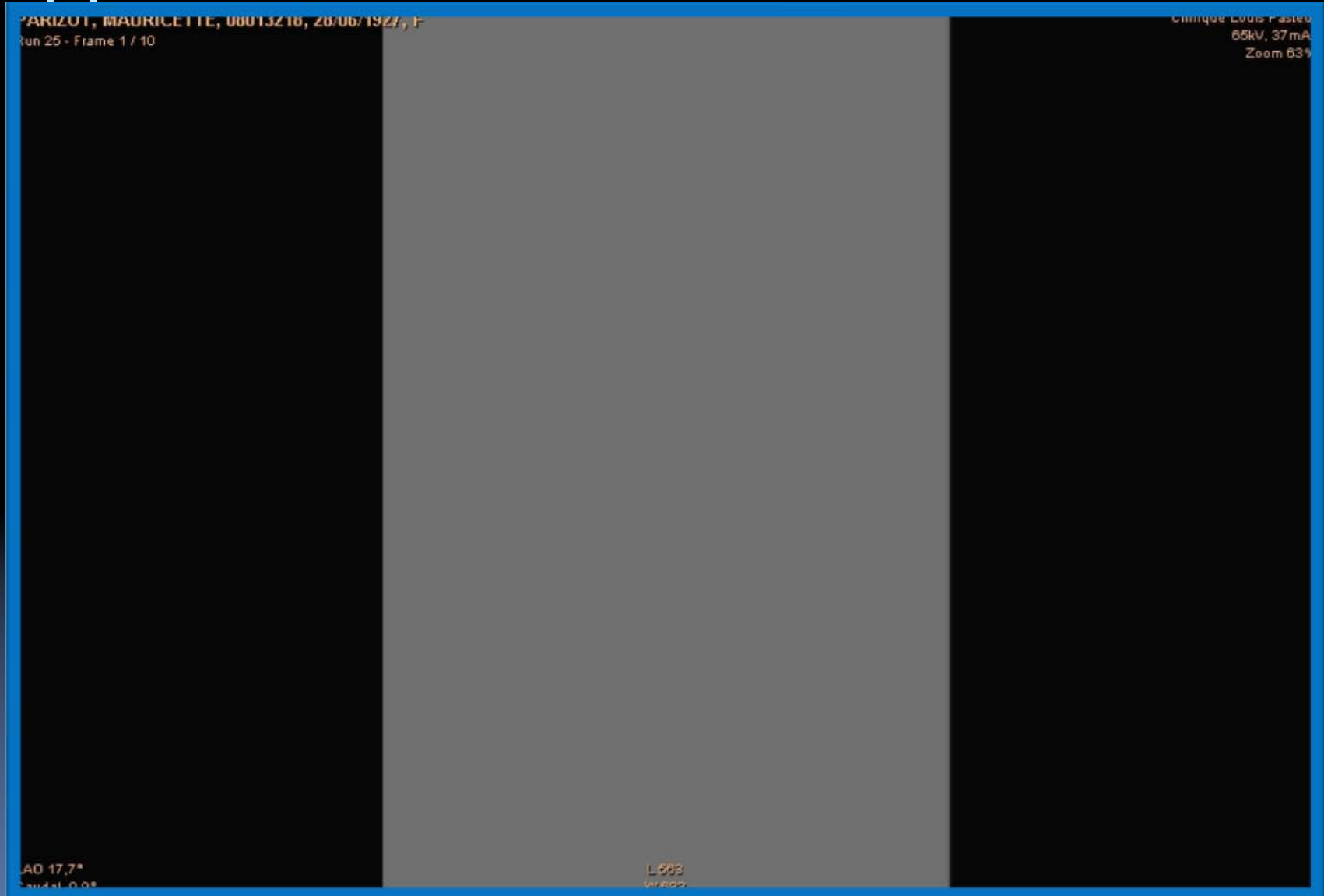


LAO 0,0°  
Cranial 0,0°

L 511  
W 931

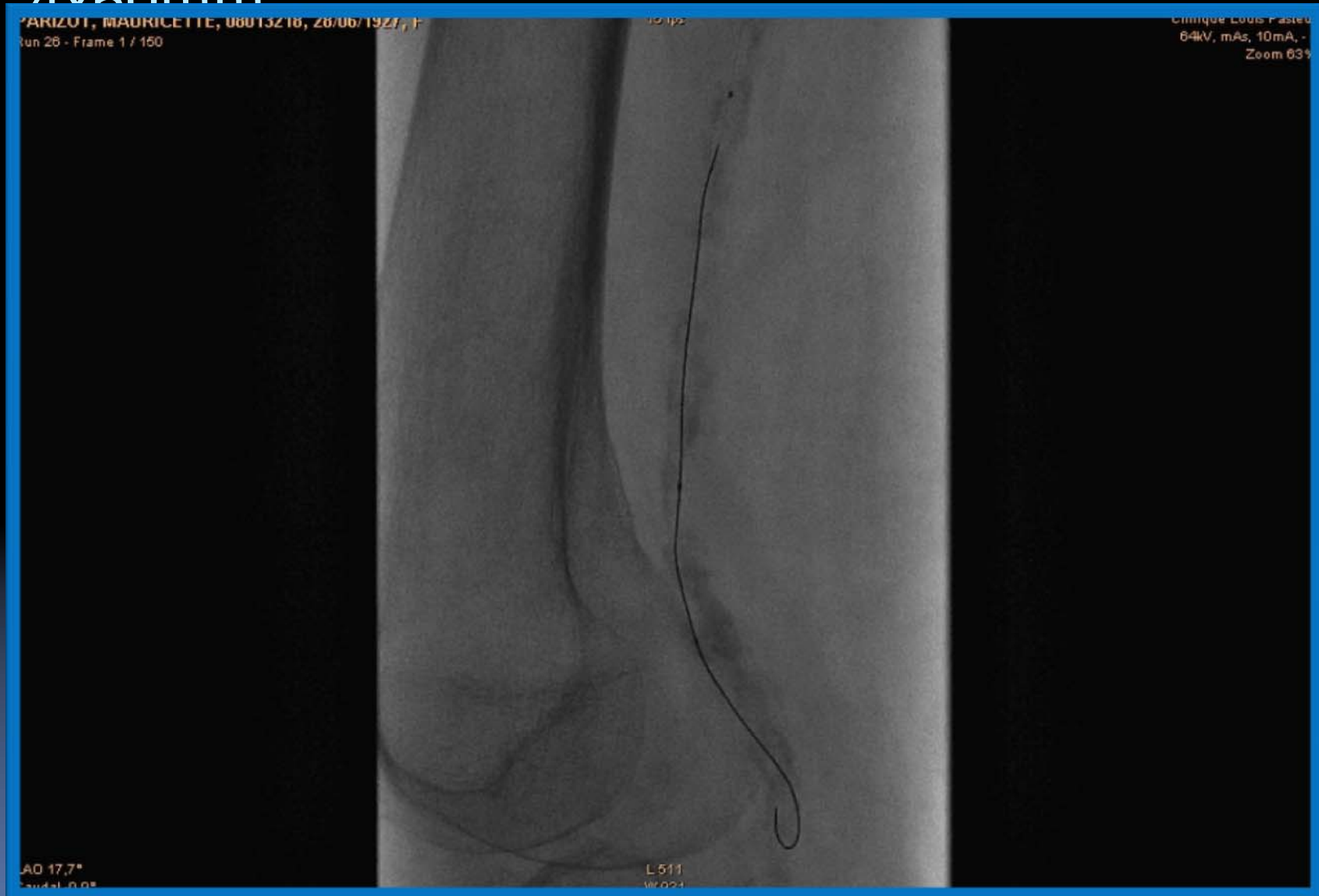# Exchange for a .14" GW ASAHI Miracle

12



# Channel enlargement : SLEEK™ Balloon

## 4x60mm



PARIZOT, MAURICETTE, 08013218, 28/06/1927, F  
Run 28 - Frame 1 / 8

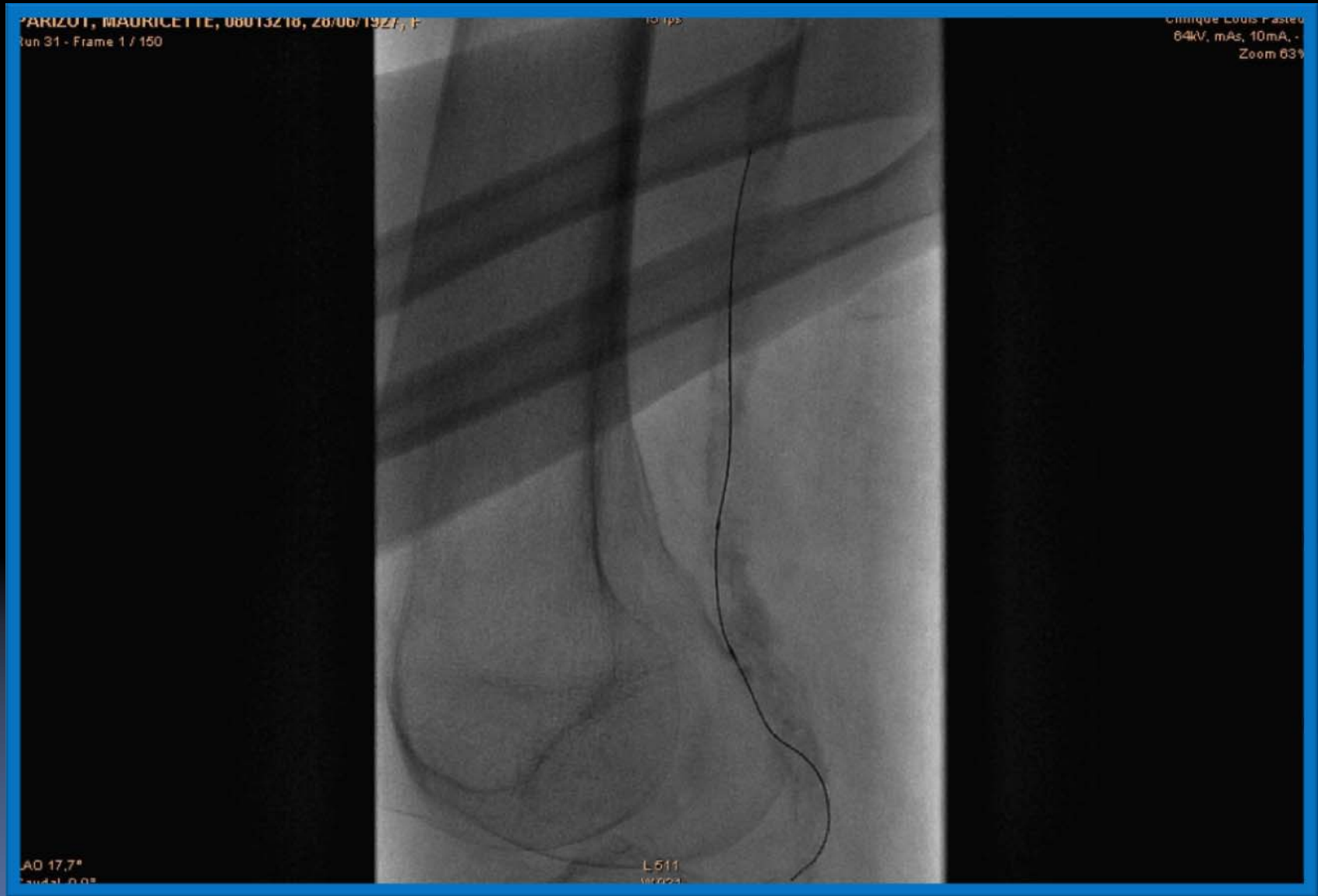
1 fps

Clinique Louis Pasteur  
65kV, 39mAs  
Zoom 63%

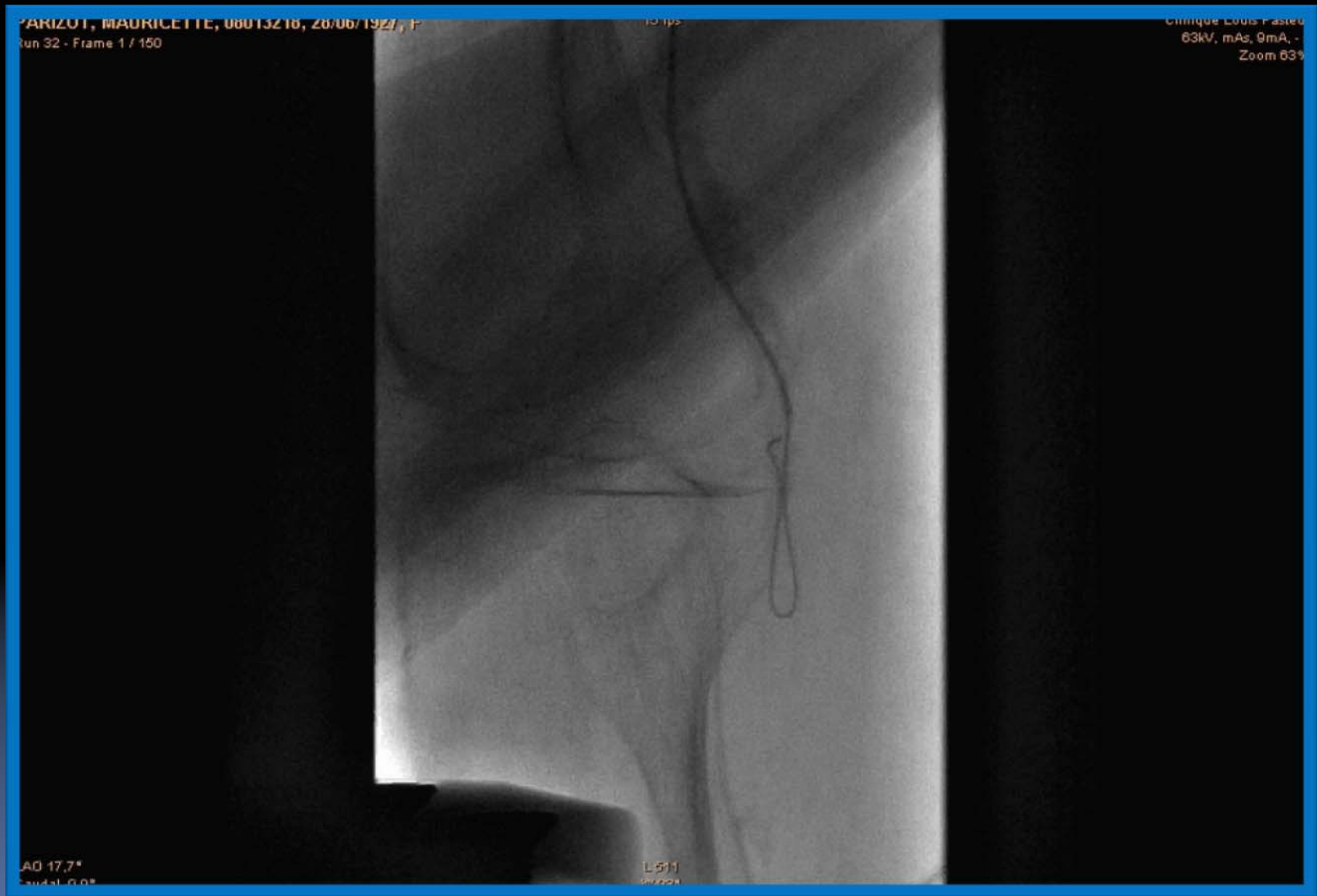
LAO 17,7°  
Caudal -0,9°

L 568  
W 688

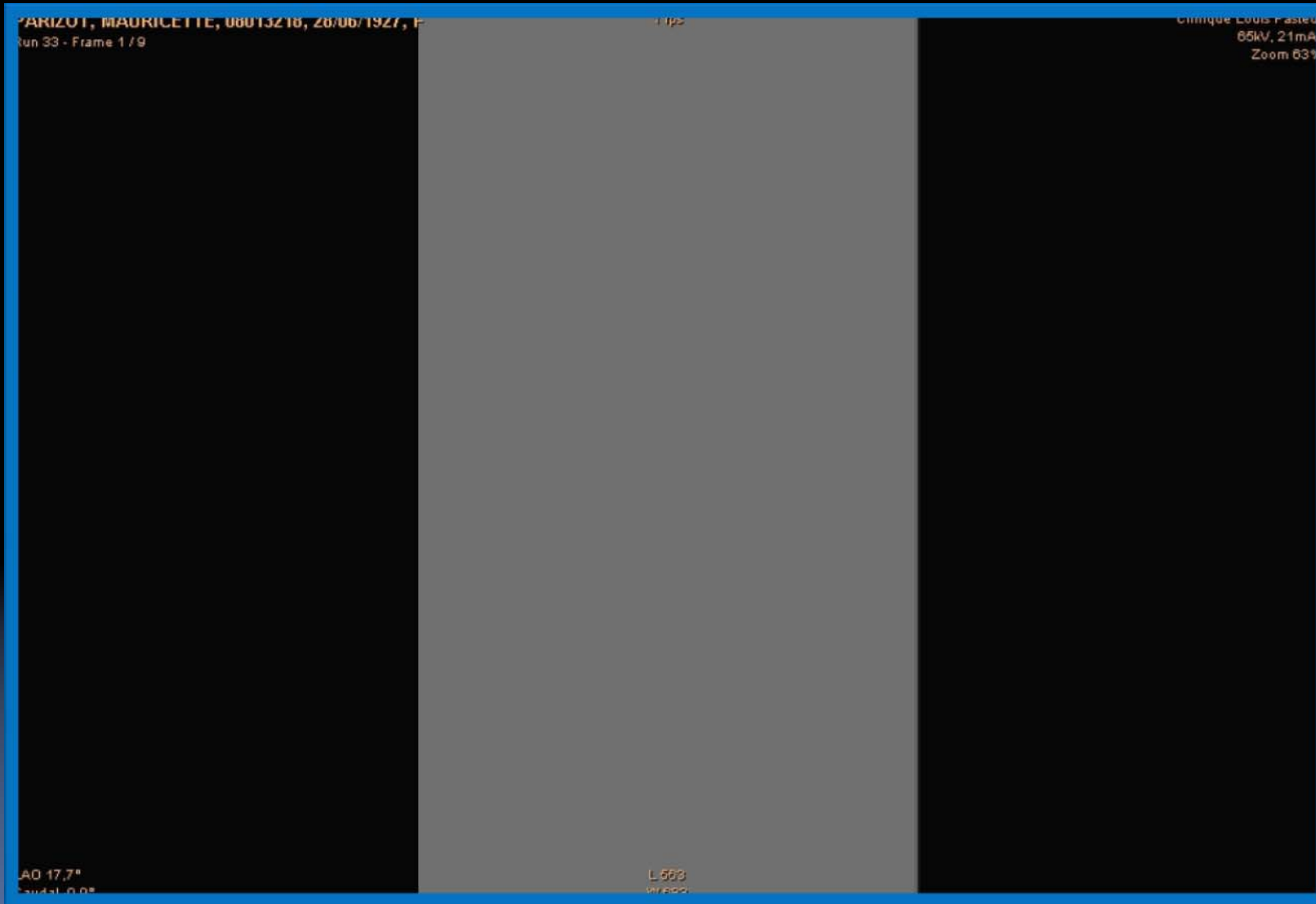
# Burst of balloon



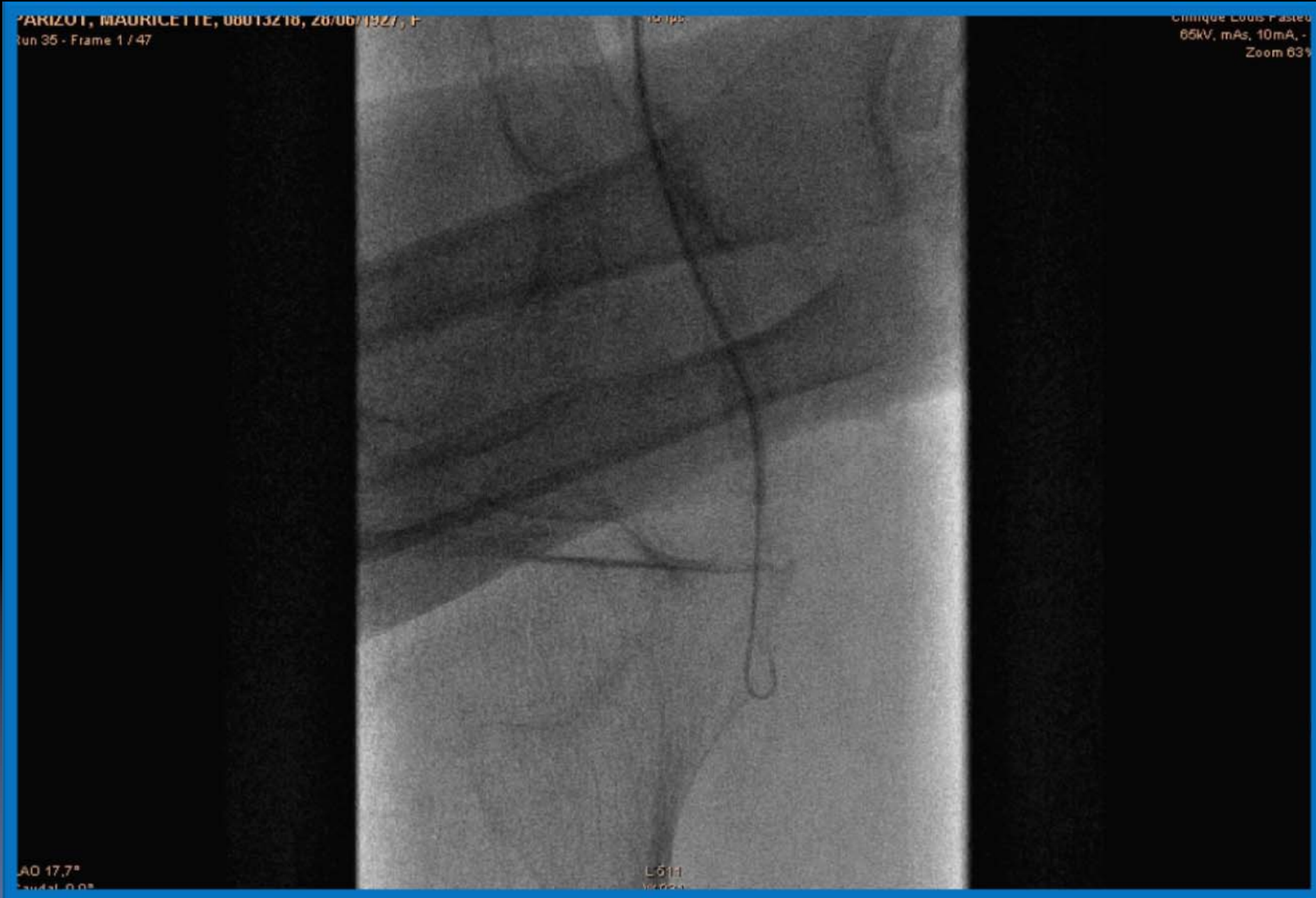
# Recanalization: Terumo catheter & J 1.5 GW



# Verification

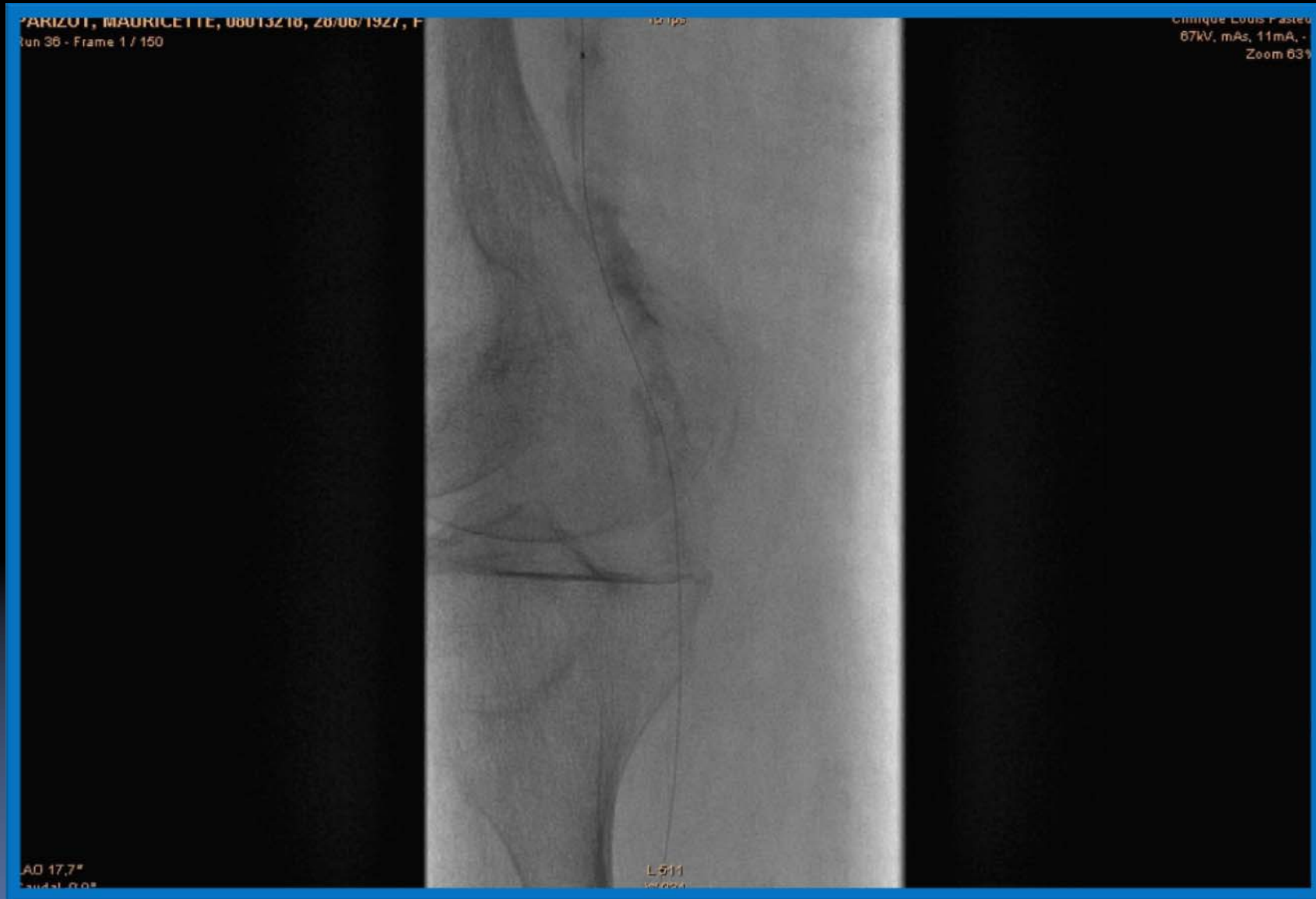

# Terumo J 1.5 Glidewire

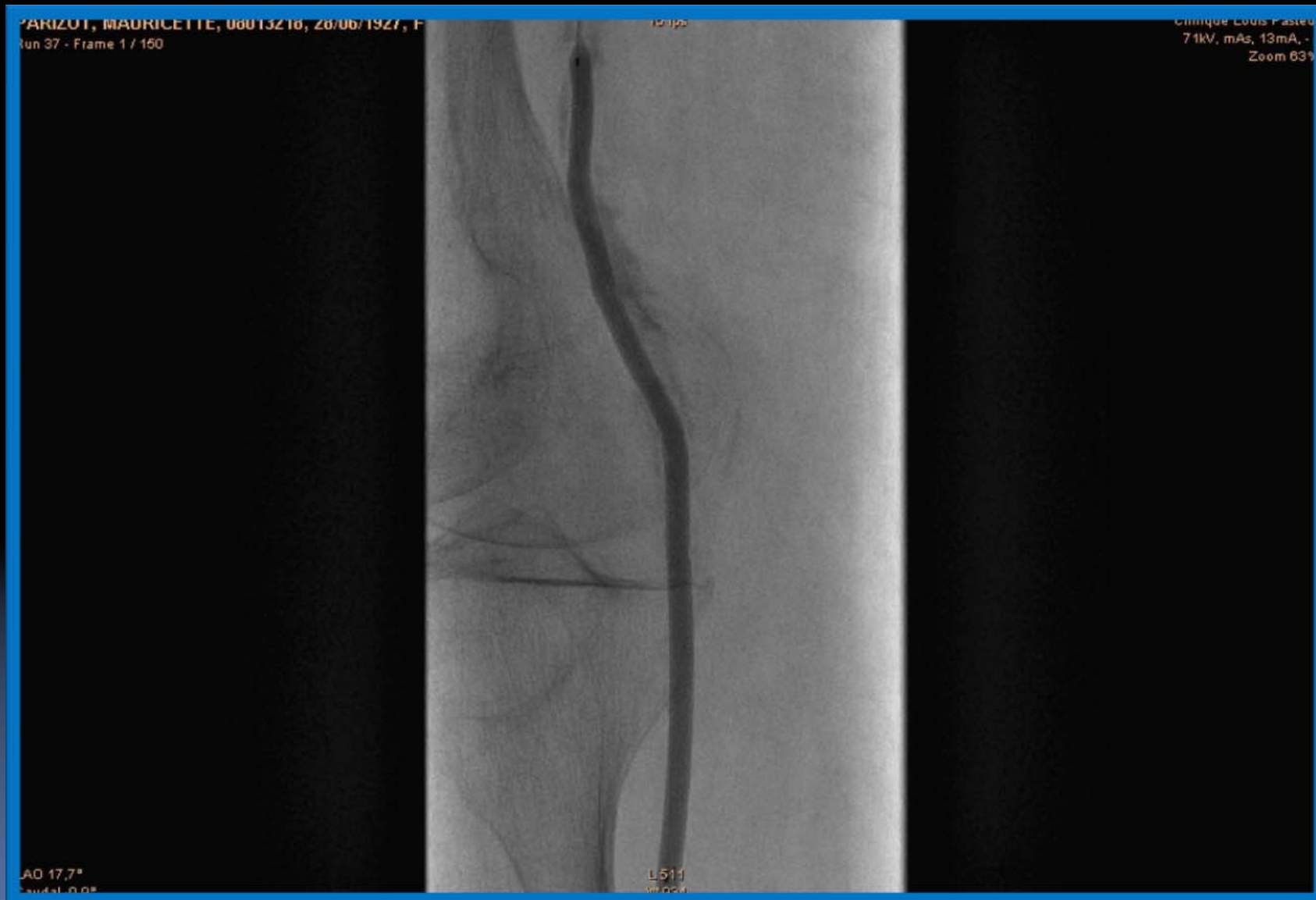



# HT intermediate 300cm / Sleek™



# SLEEK™ BALLOON CORDIS 3.5x 120mm



PARIZOT, MAURICETTE, 08013218, 28/06/1927, F  
Jun 30 - Frame 1 / 6

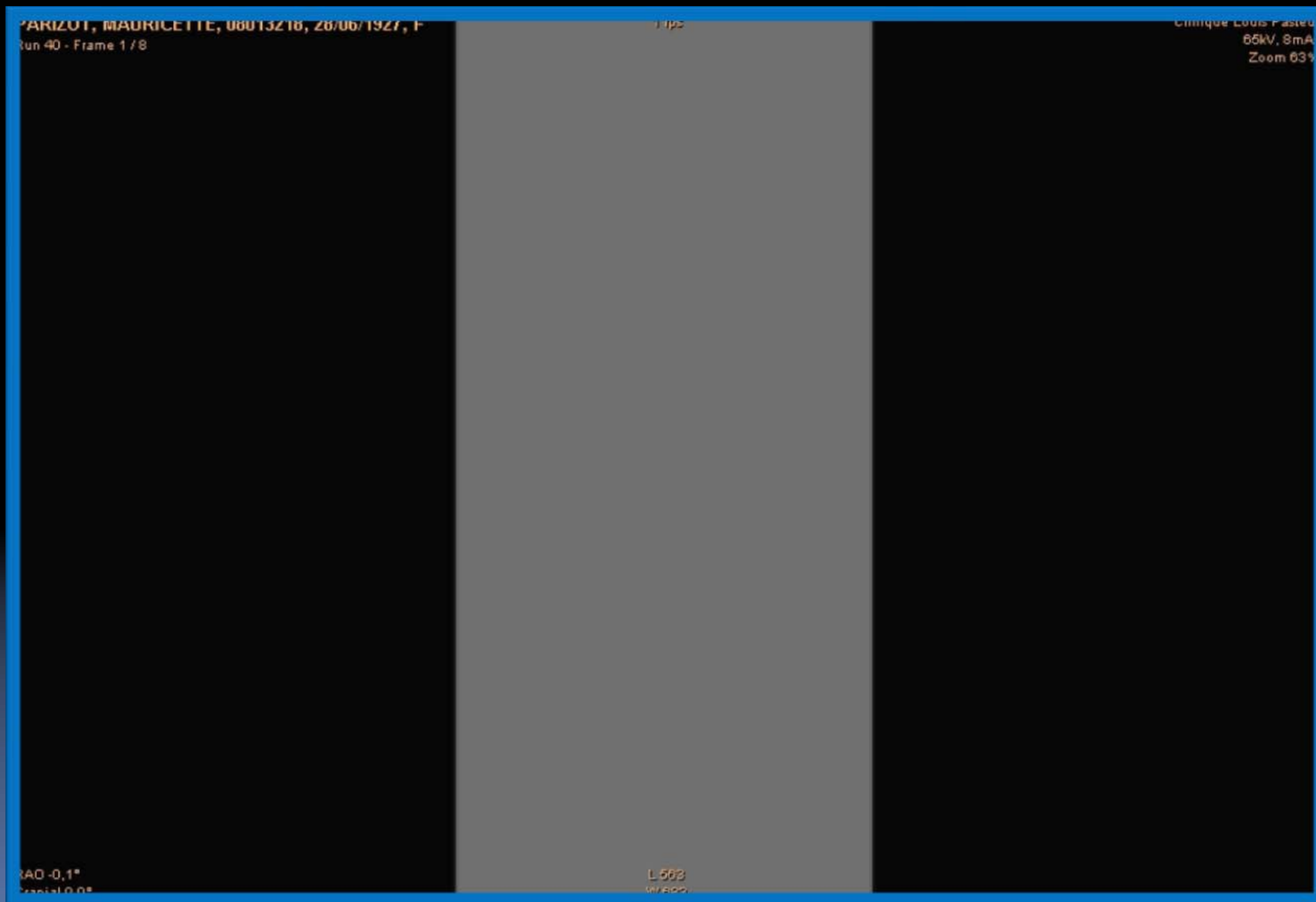
0195

Clinique Louis Pasteur  
65kV, 24mA  
Zoom 63%

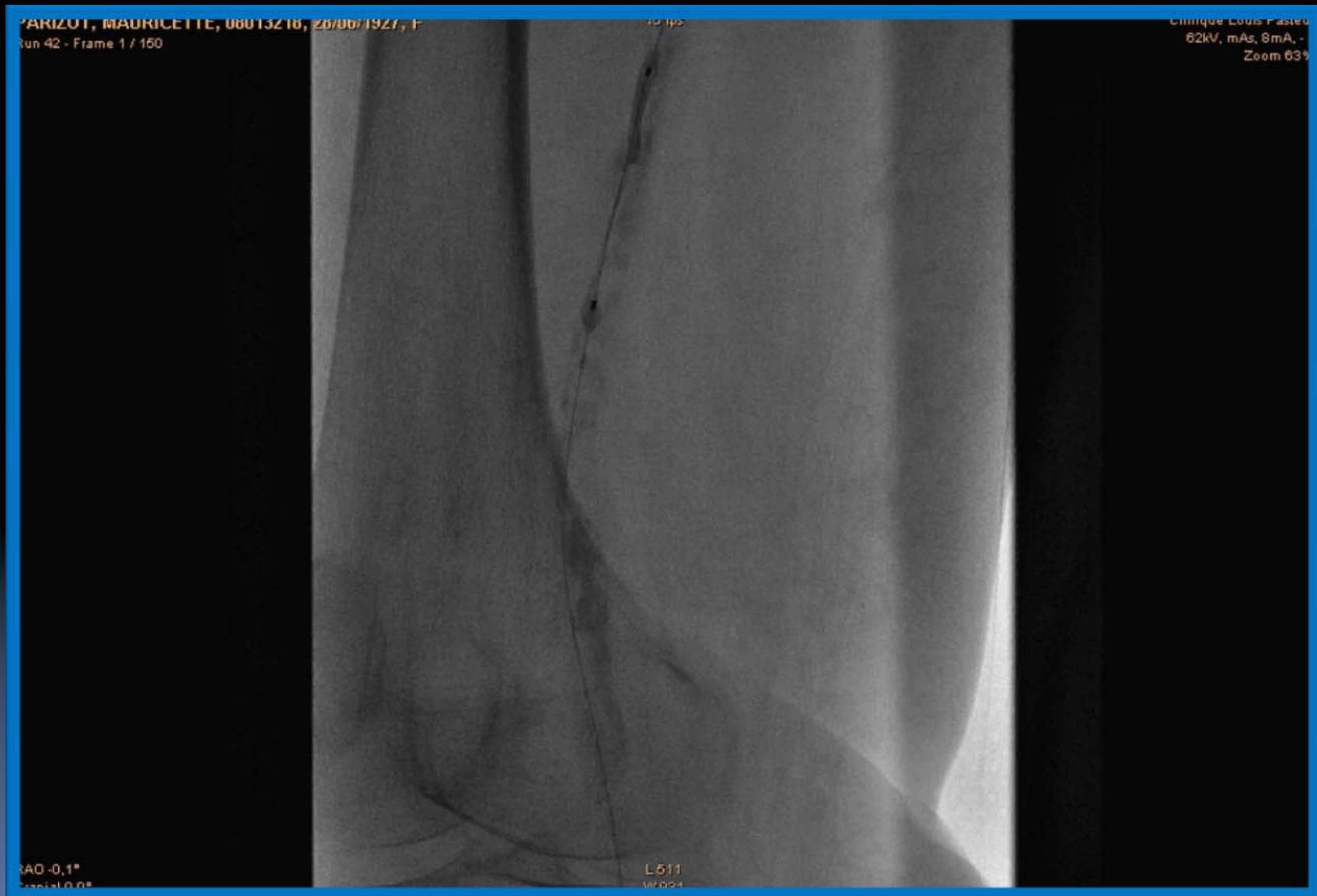AO 17,7°  
Caudal 0,08

L 503  
019500

# Distal leg arteries after angioplasty



# Slalom™ Balloon Cordis 5x40mm



# After balloon dilatation & before

PARIZOT, MAURICETTE, 08013218, 28/06/1927, F  
Run 48 - Frame 1 / 7

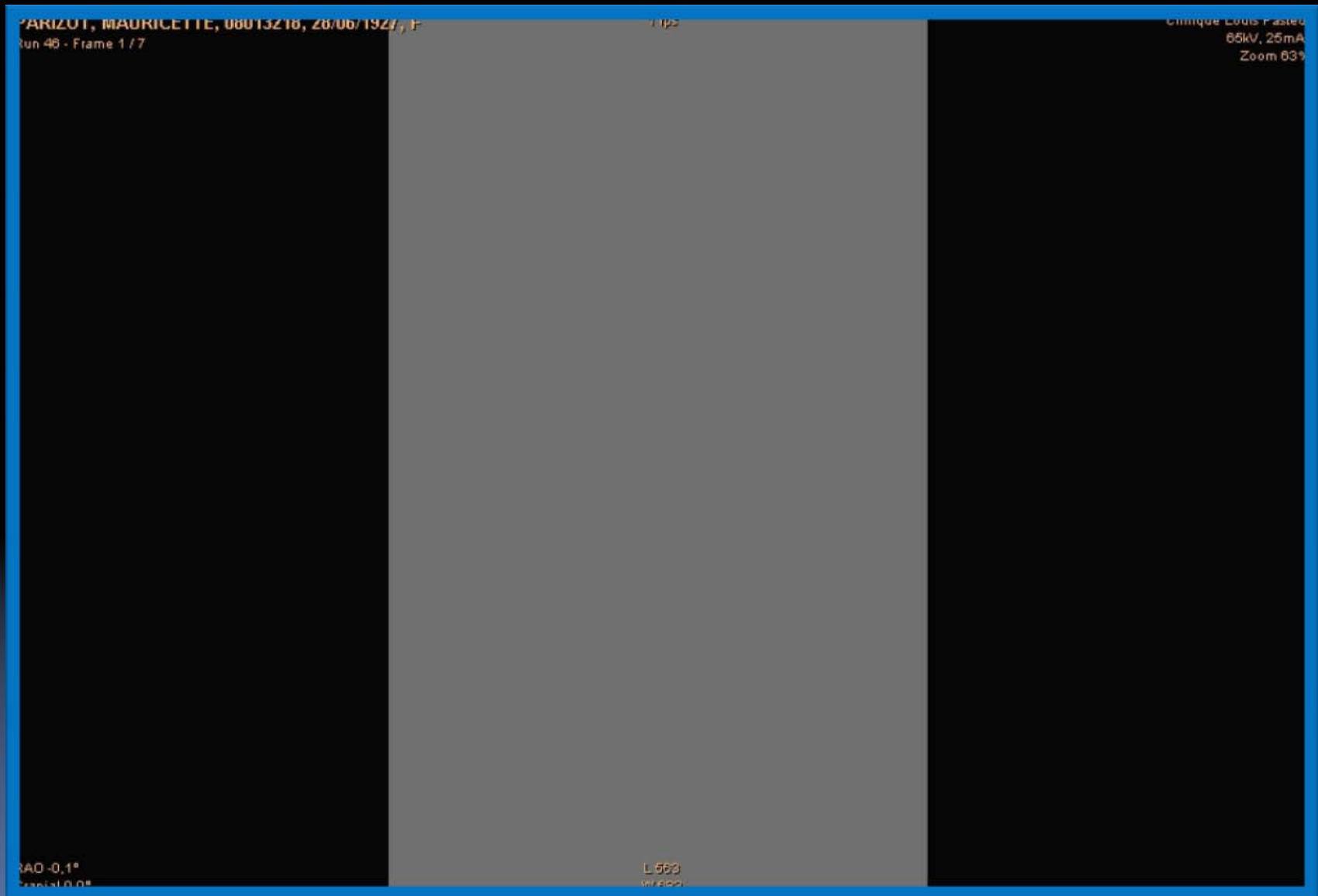
1 fps

Clinique Louis Pasteur  
65kV, 25mAs  
Zoom 63%


RAO -0,1°  
Cranial 0,0°

L 588  
W 688

# Placement of LIFESTENT™ Bard 7x100

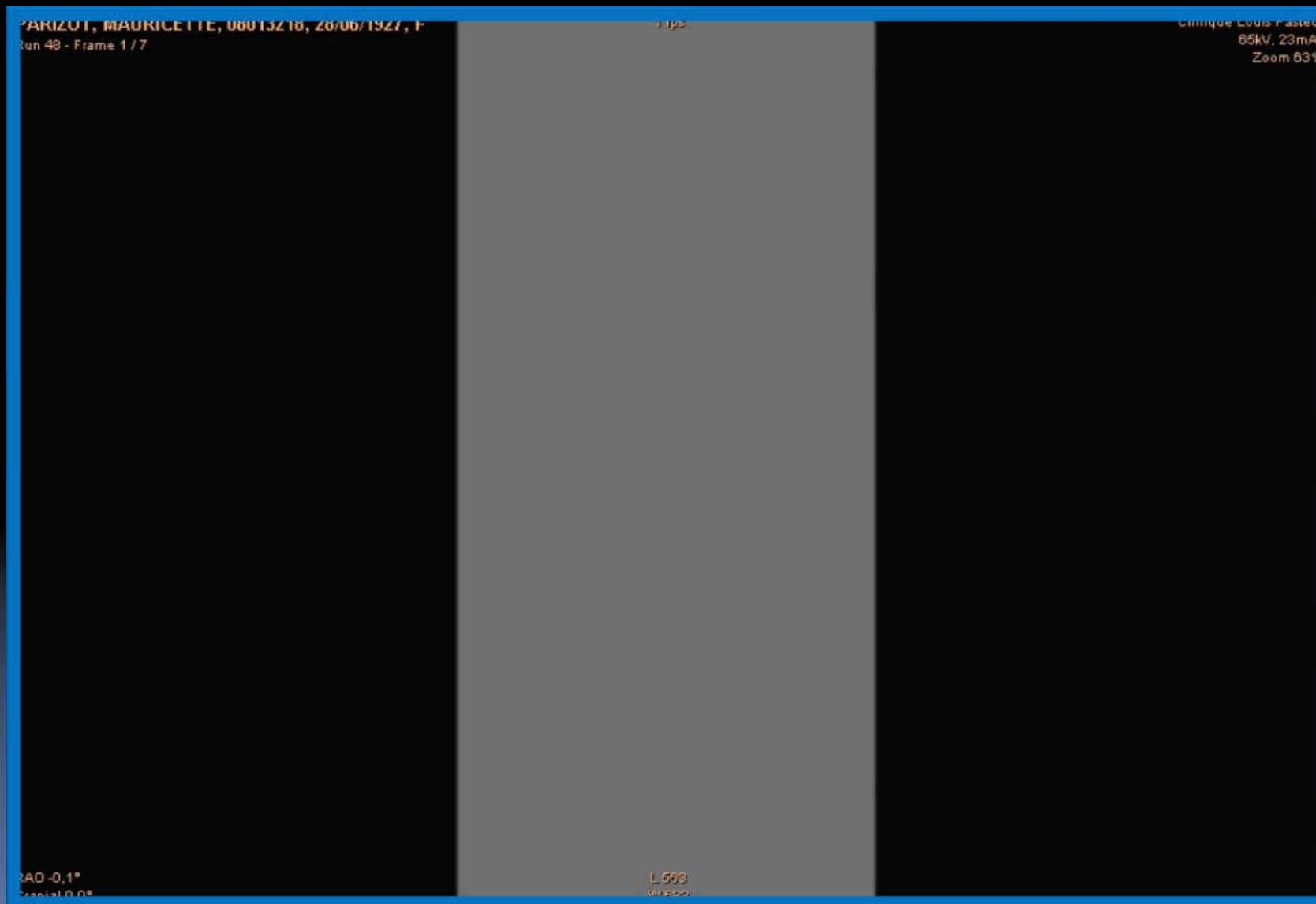


# Final Result





# Final result





# **SECOND CASE PATIENT 4**

**MAX AMOR**

**GERARD ETHEVENOT, ZUKAI CHATI**

**CLINIQUE LOUIS PASTEUR**

**ESSEY-LES-NANCY , FRANCE**



# **TIBIO-PERONEAL ARTERIES ANGIOPLASTY & STENTING FOR A HEAVILY CALCIFIED STENOSIS**

**MAX AMOR**

**GERARD ETHEVENOT, ZUKAI CHATI, CLAUDE AMICABILE**

**CLINIQUE LOUIS PASTEUR**

**ESSEY-LES-NANCY , FRANCE**

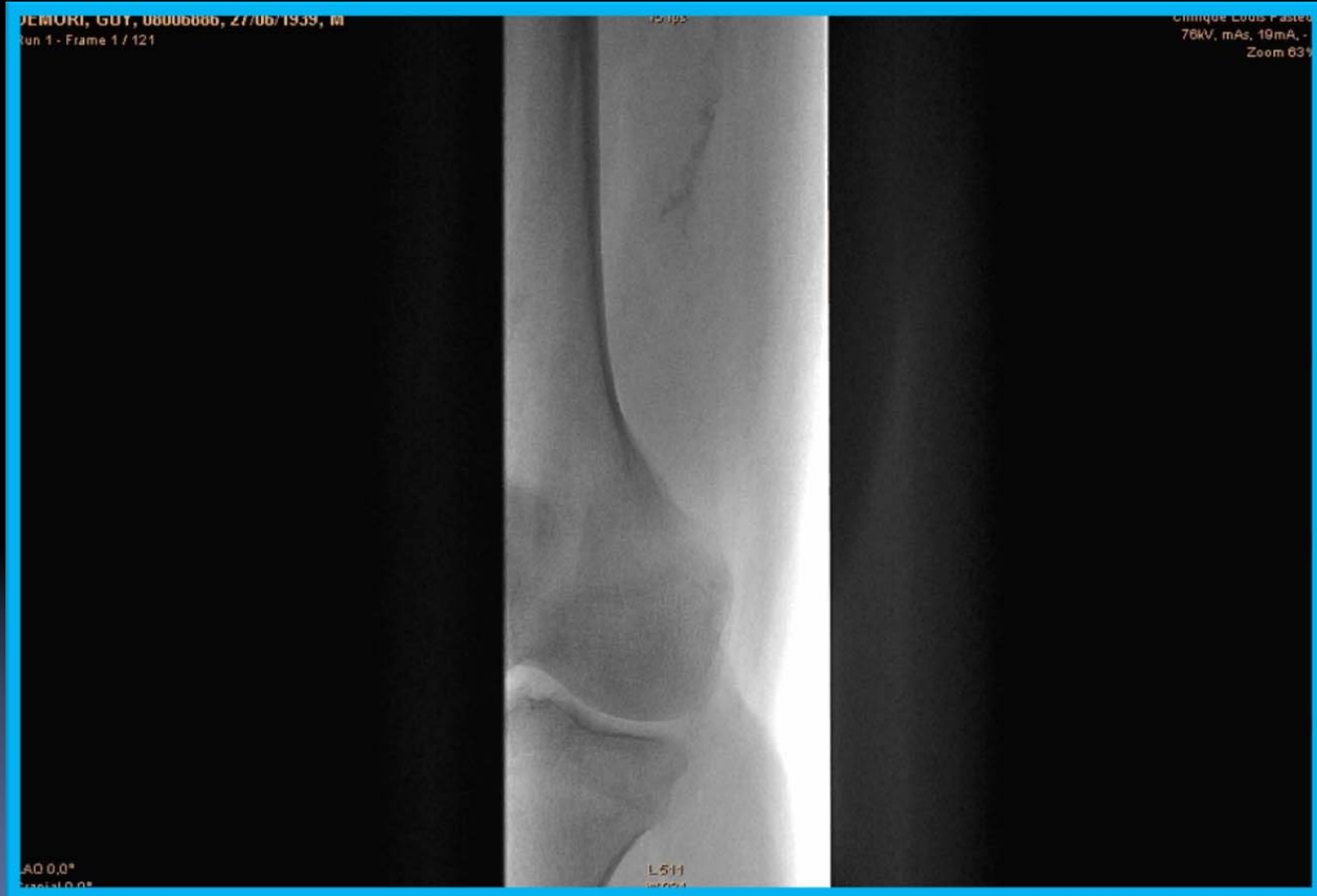# History

- 70 years old man
- Severe symptomatic claudication despite medical therapy
- Referred for endovascular management

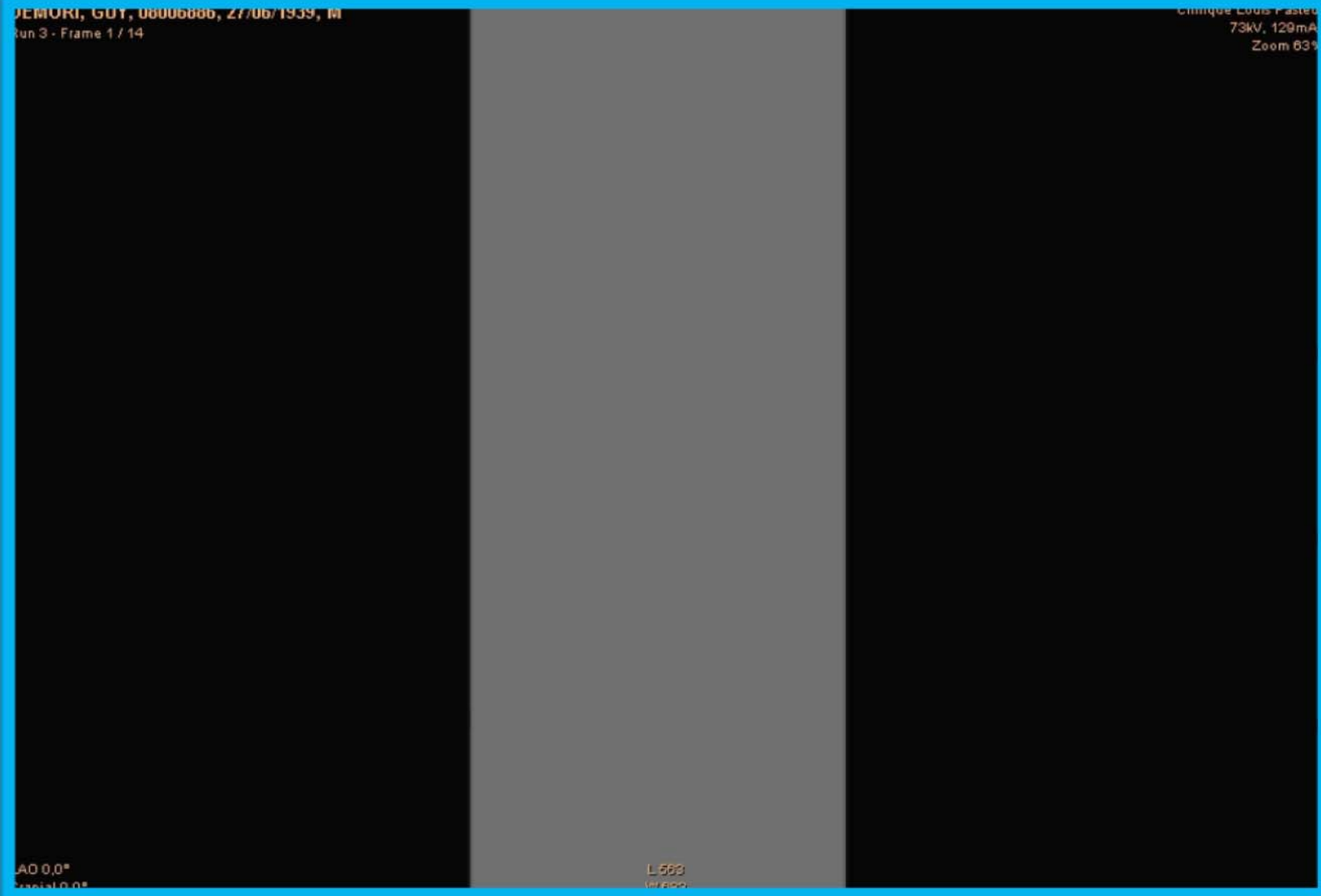
# Procedure

- 6F Right Antegrade Femoral Approach
- Multilevel angioplasty and stenting

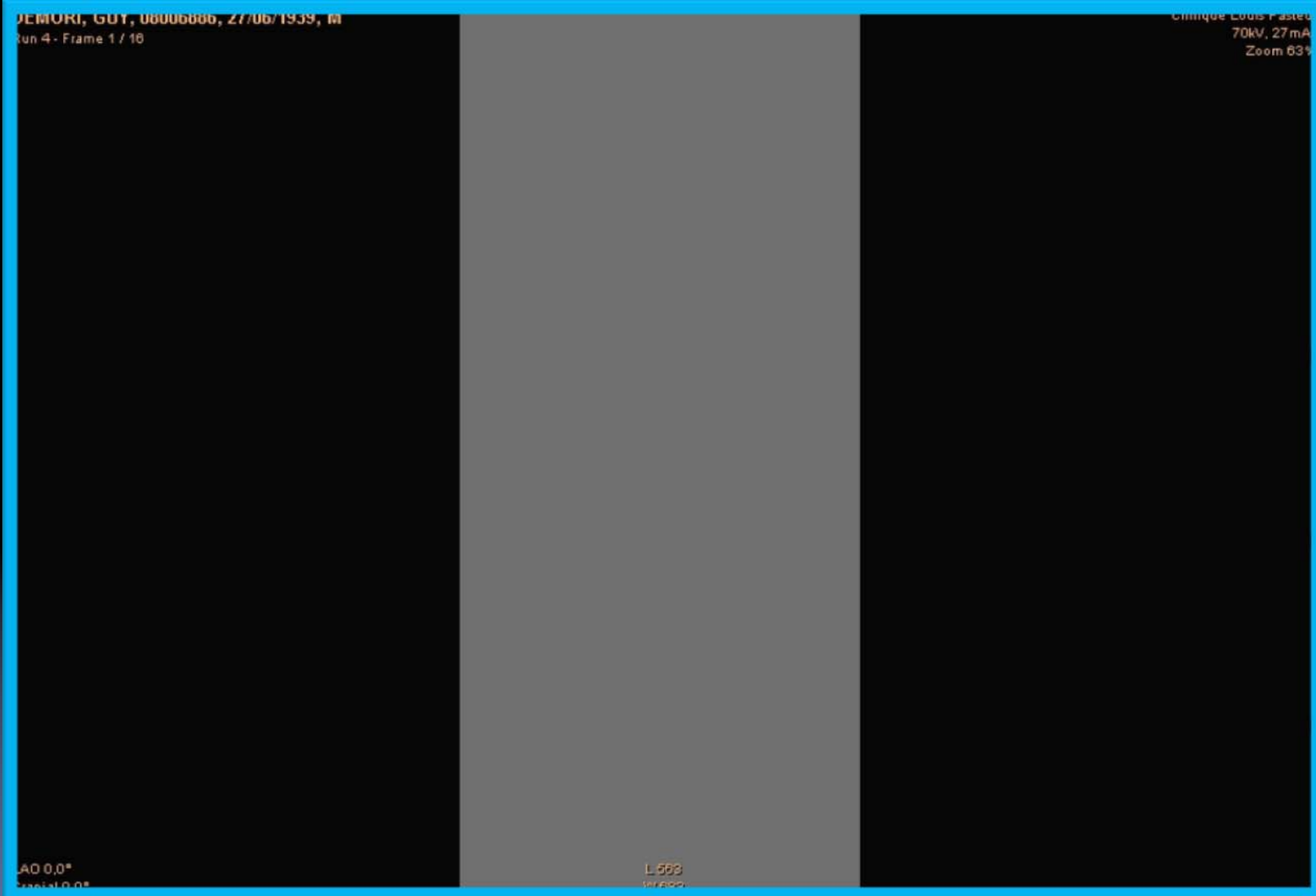
# Antegrade ; COOK Micro-puncture



# Femoral level : Irregularities

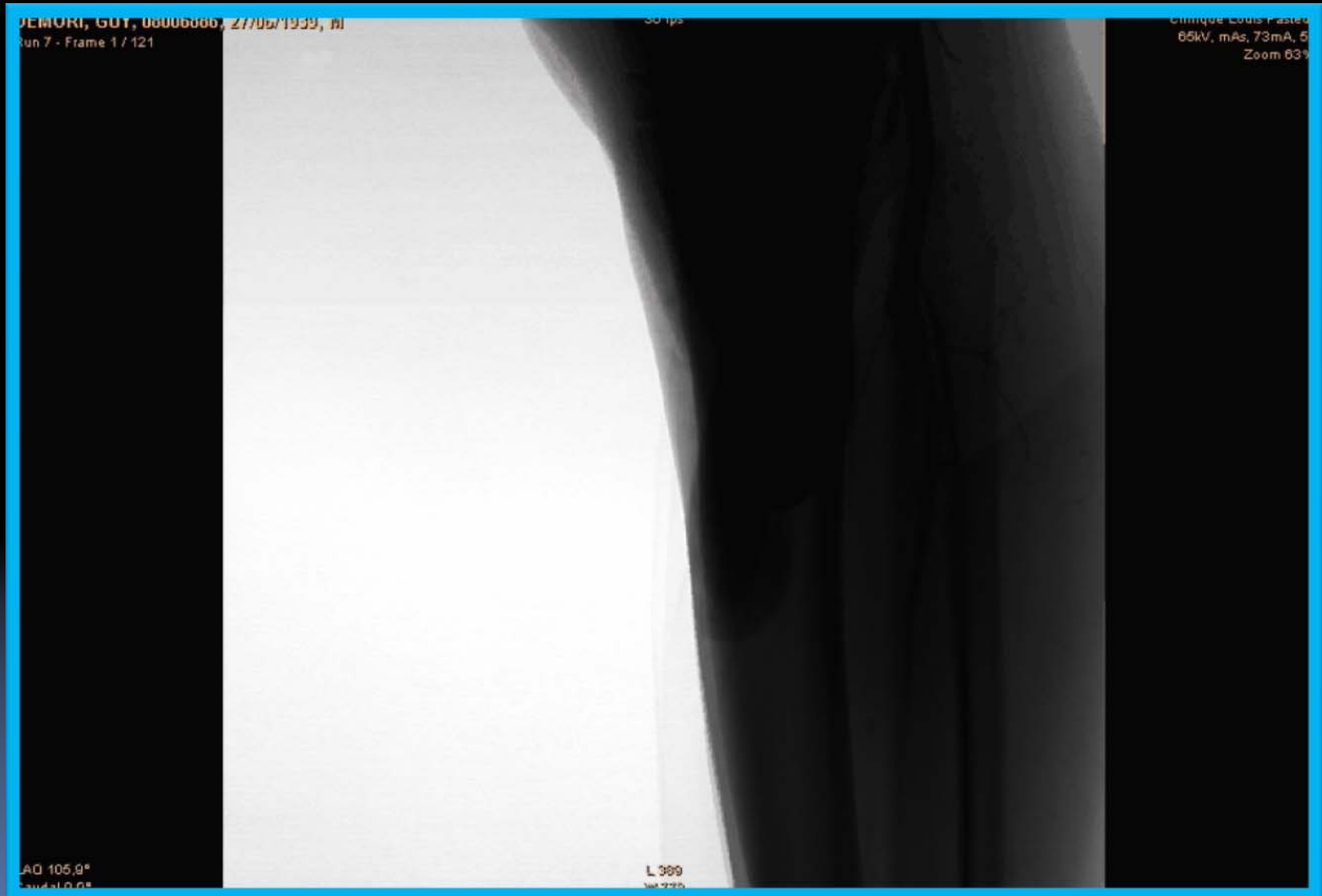


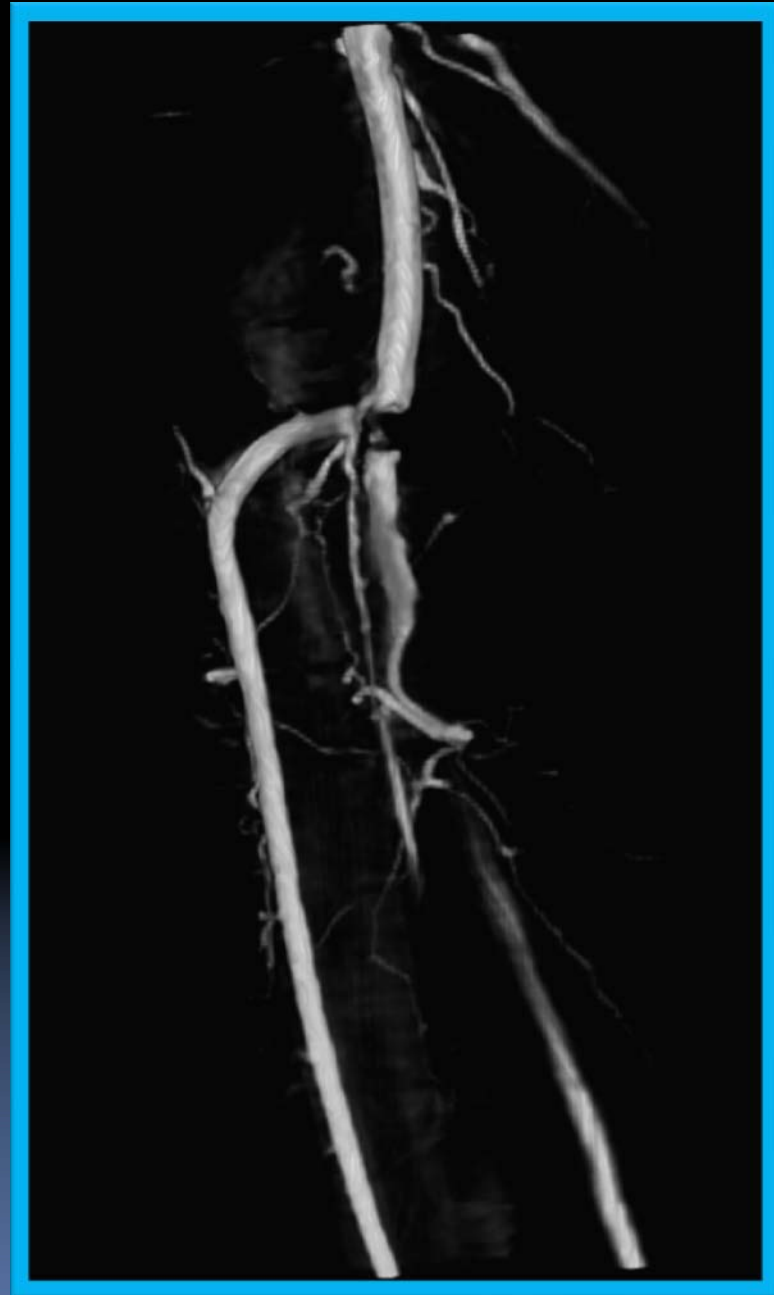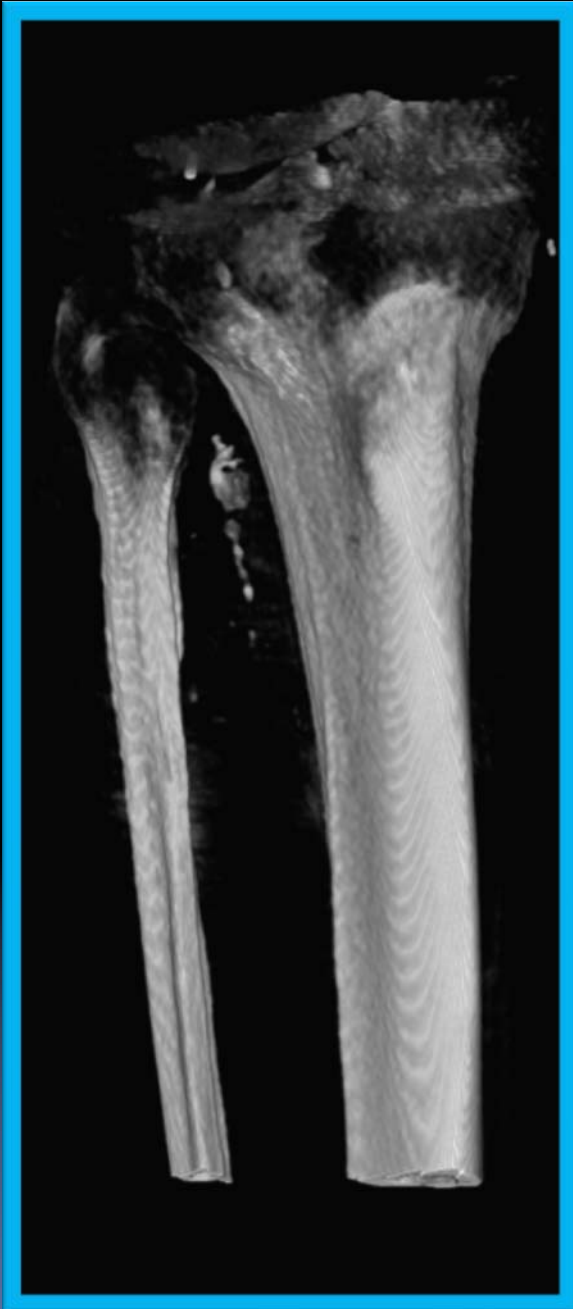# Calcareous Massif of the tibio-peroneal Trunk



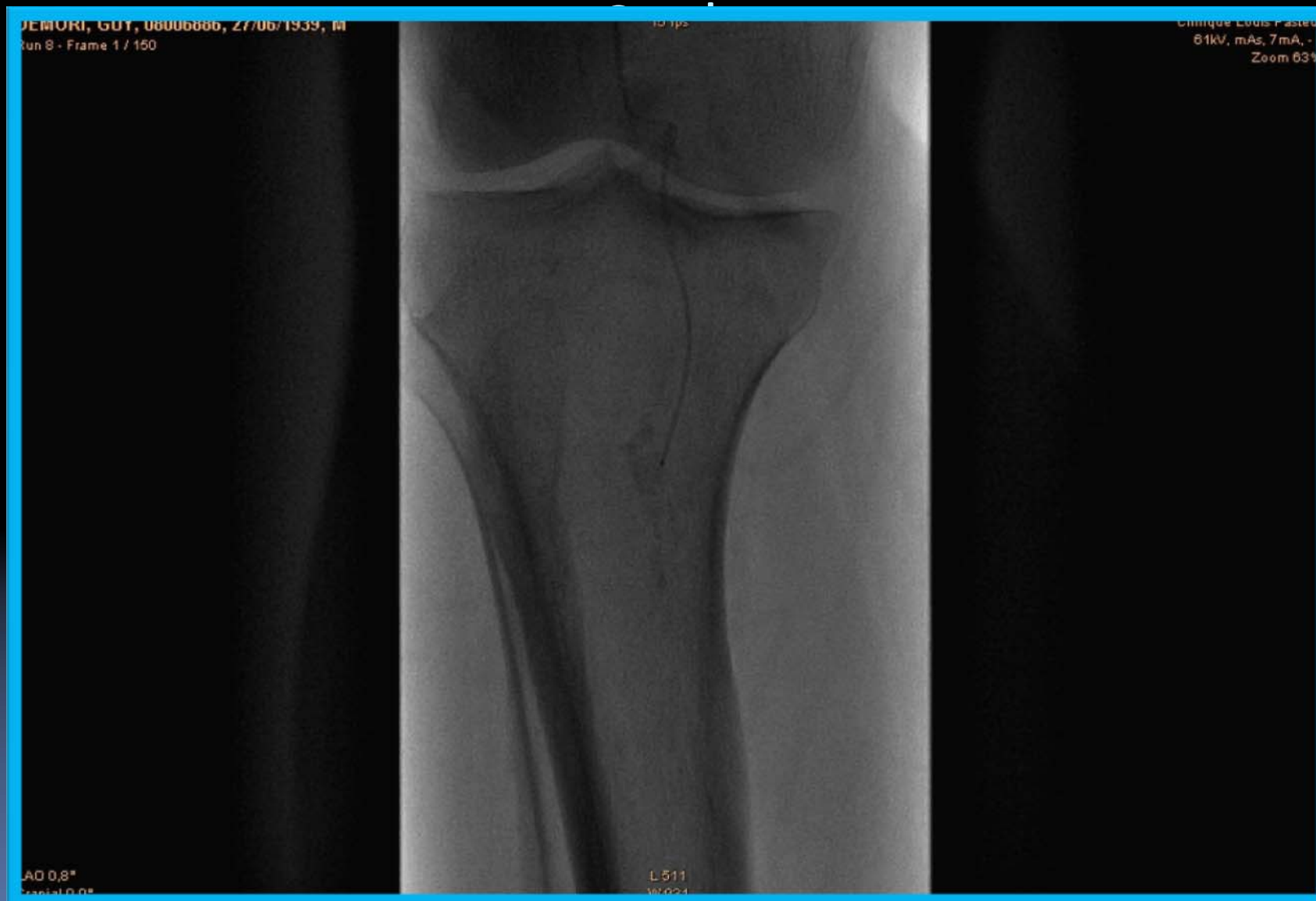


# 3D Rotational Angiography: 121 images in 4 seconds

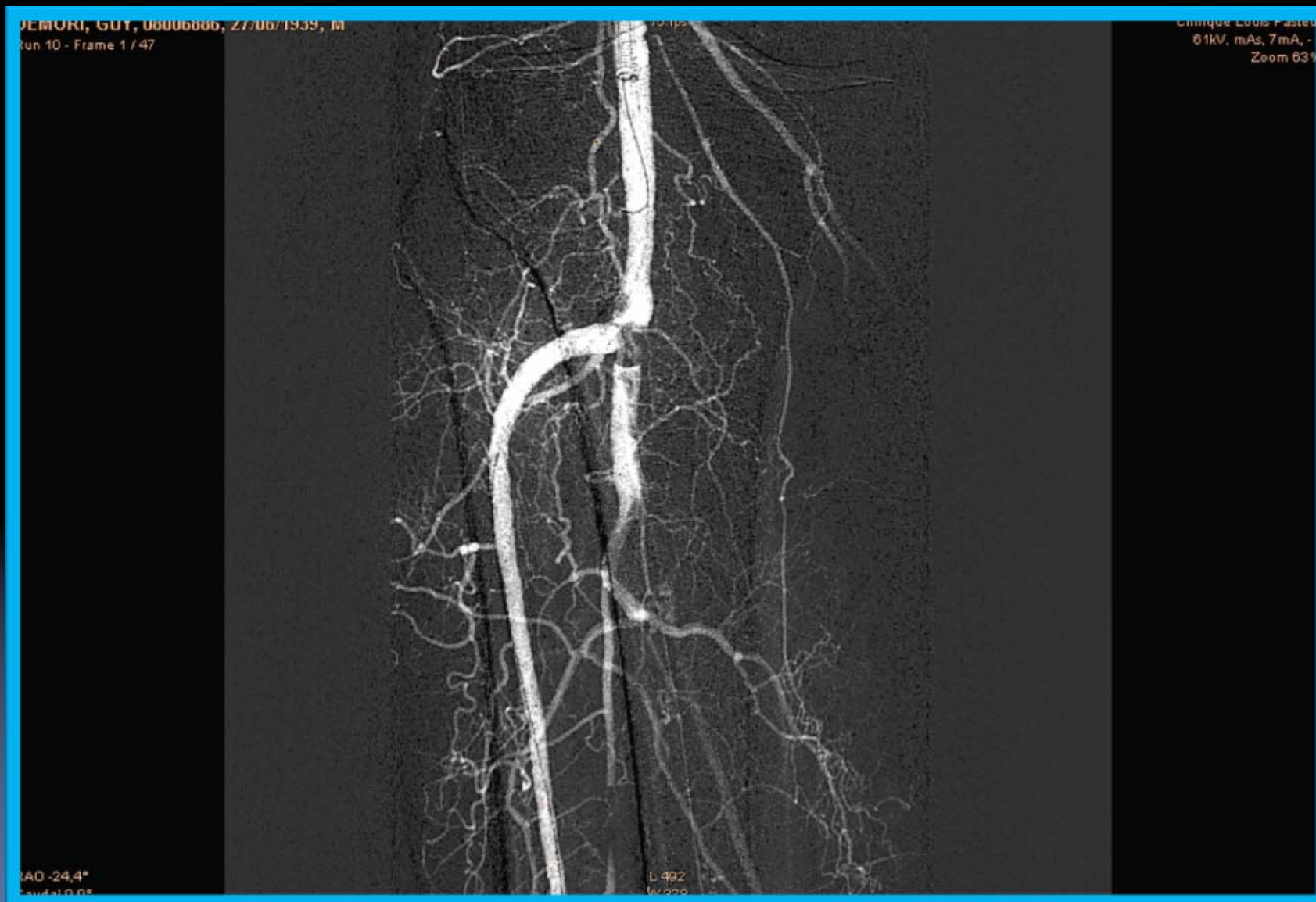



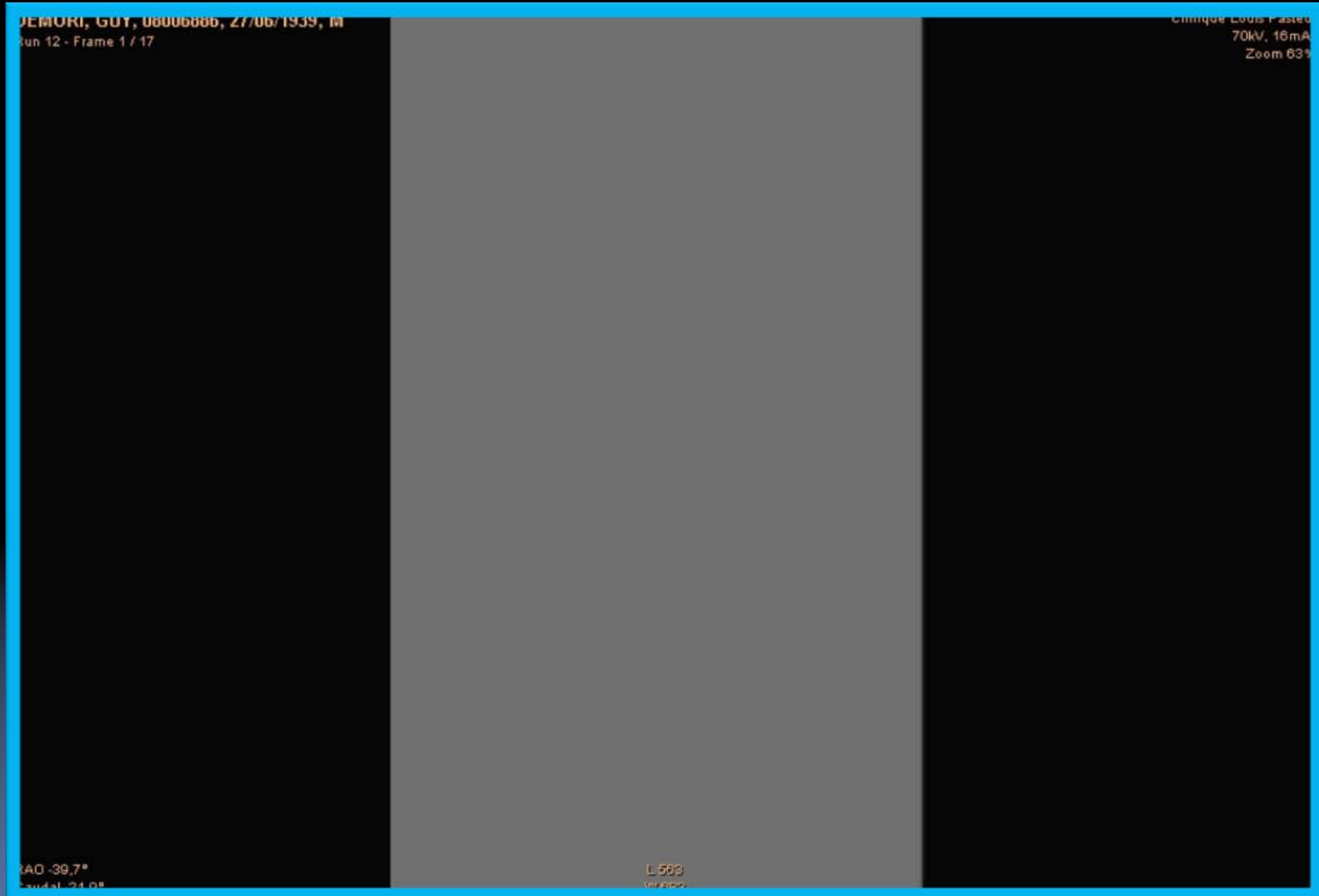
# Placement of a 45 cm Braided introducer



# Road Mapping



# Selective injection . Pilot 200 GW Abbott

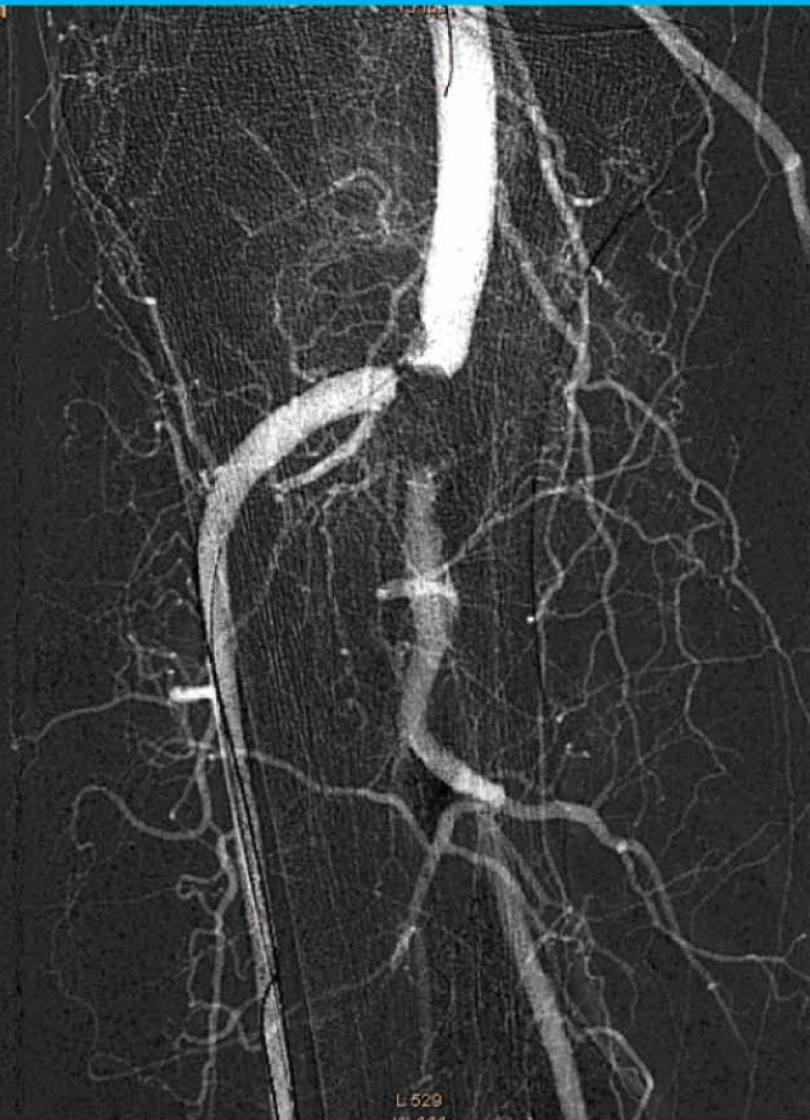

JEMORI, GUY, 00006000, Z7/06/1939, M  
Jun 14 - Frame 1 / 148

Clinique Louis Pasteur  
61kV, mAs, 8mA, -  
Zoom 63%

RAD -1,7°  
axial -1,7°

L 529  
W 433



# Failure to position a second GW

JEMORI, GUY, 080066886, 27/06/1939, M  
Run 17 - Frame 1 / 15

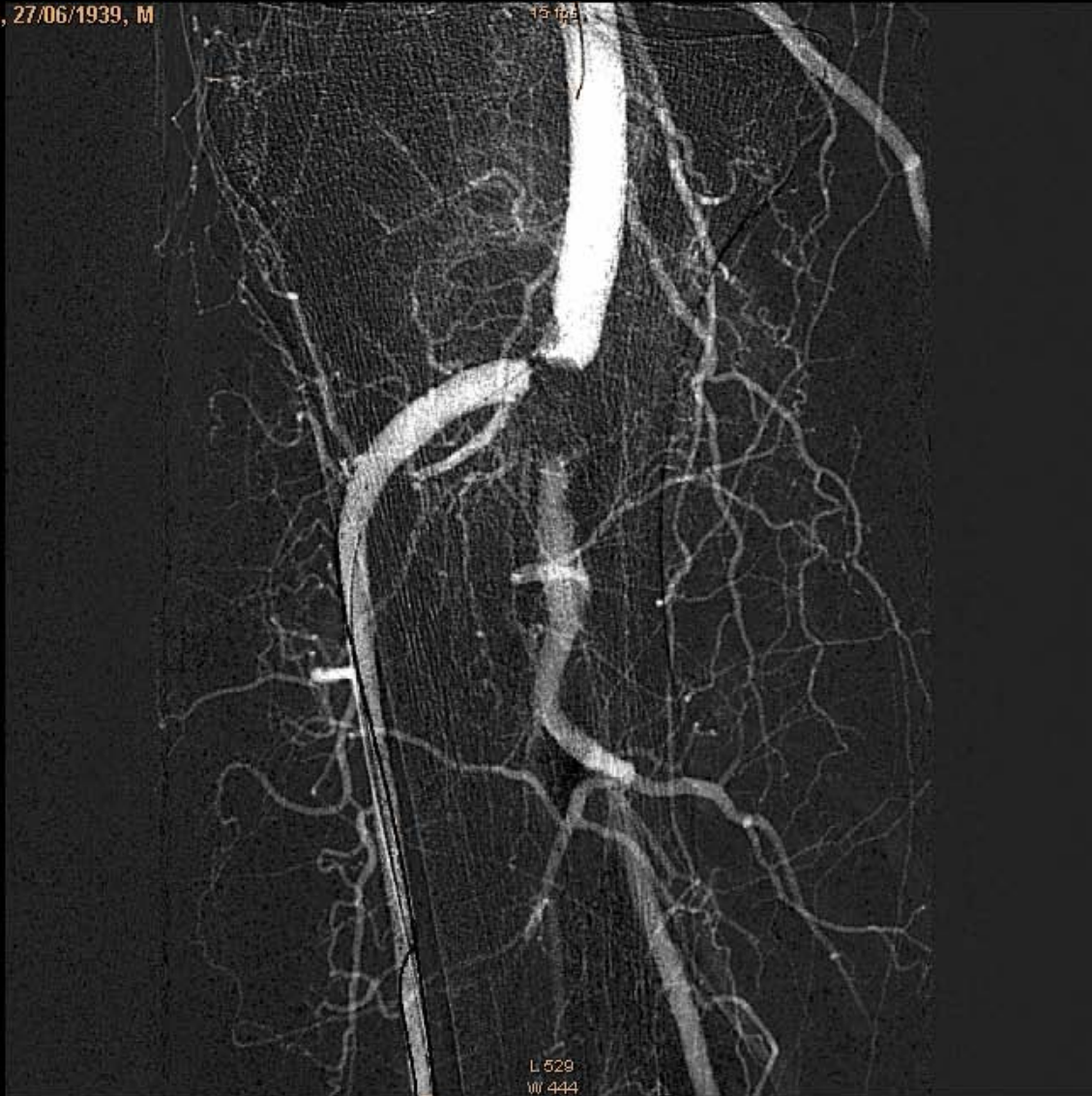Cinique Louis Pasteur  
80kV, 15mA  
Zoom 63%



RAD -1.7°  
Azimut -1.7°

L 563  
W 682

DEMORI, GUY, 08006886, 27/06/1939, M  
Run 14 - Frame 1 / 148



Clinique Louis Pasteur  
61kV, mAs, 8mA, - s  
Zoom 63%

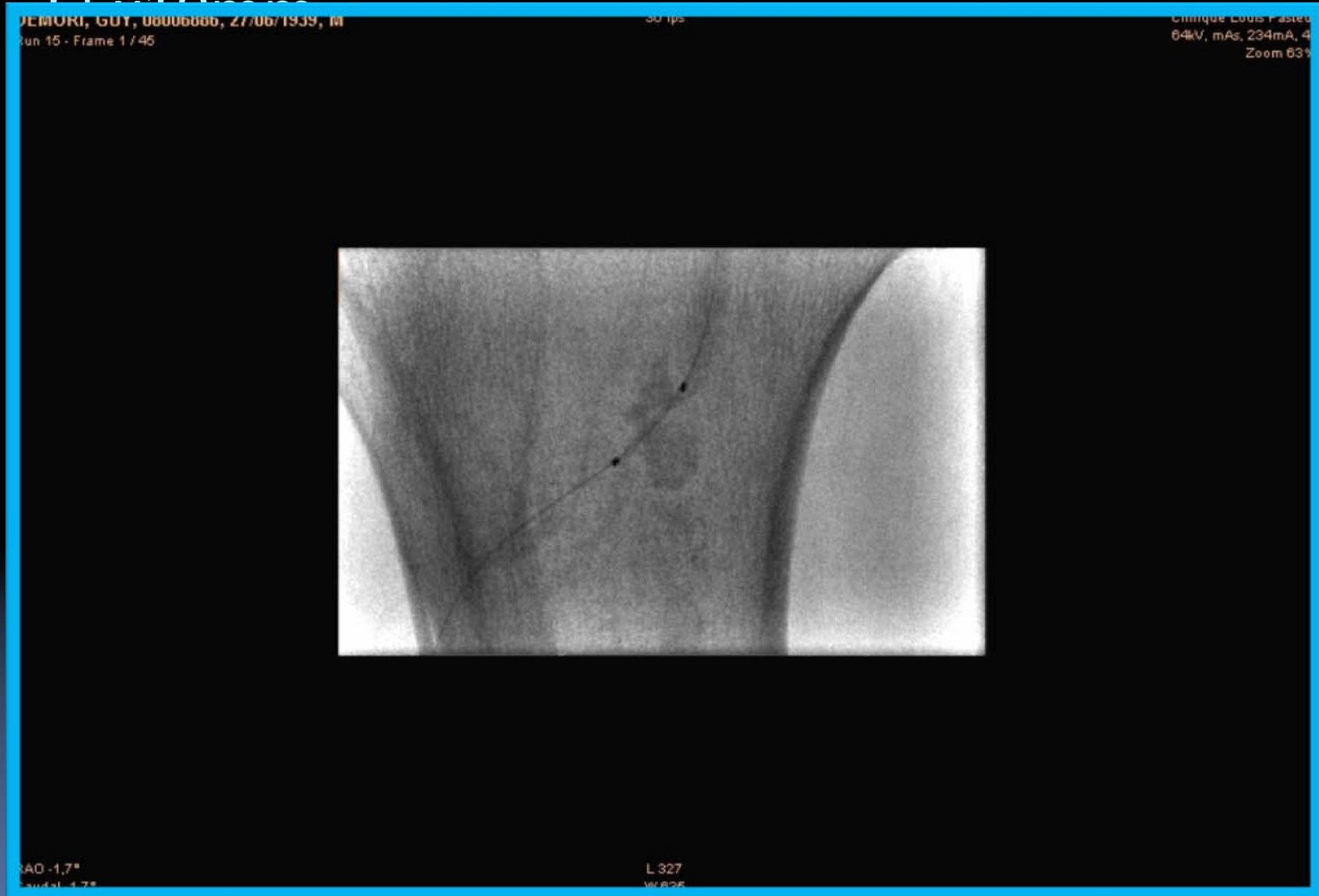RAO -1,7°  
Caudal -1,7°

L 529  
W 444

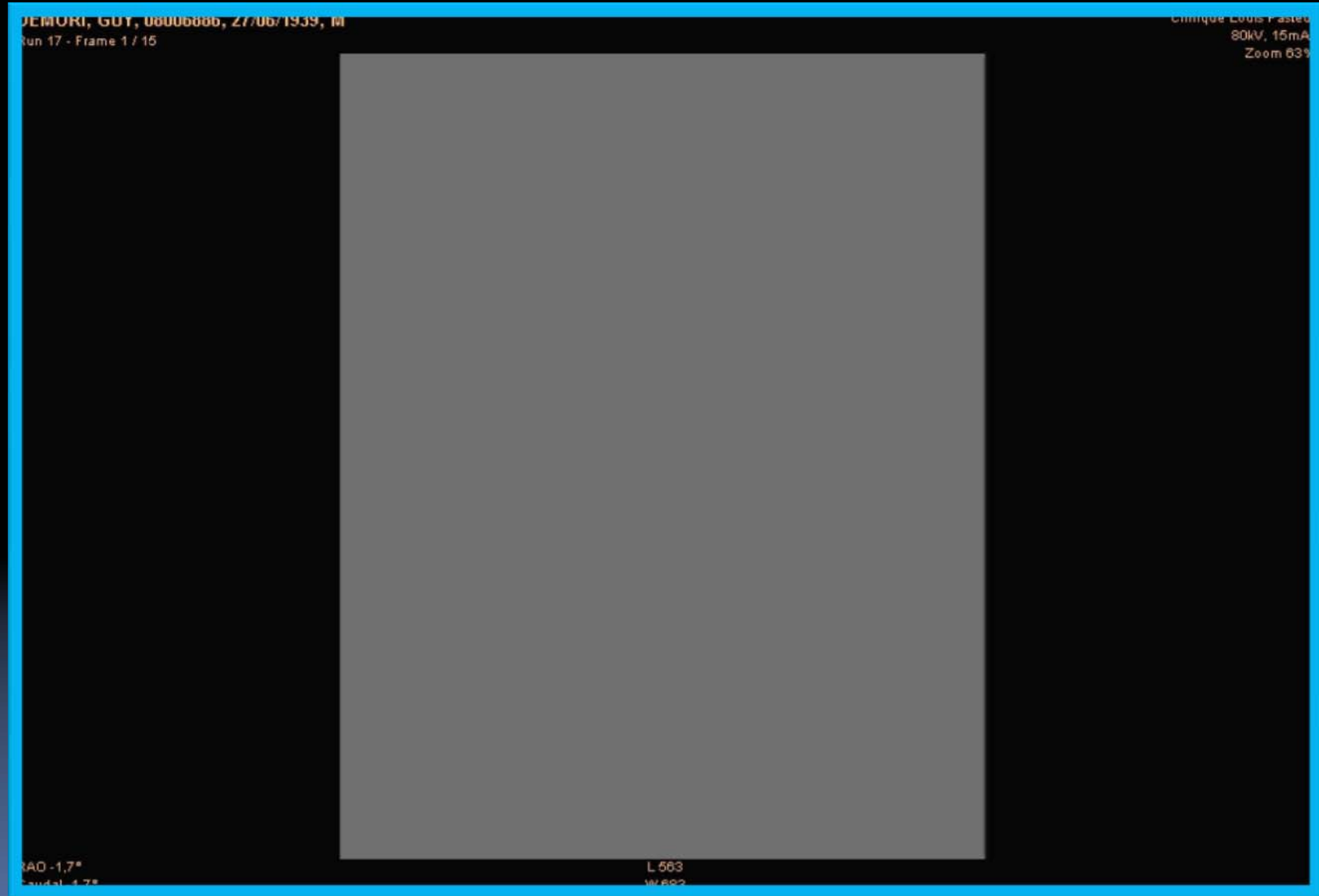


# Dilatation with a cutting balloon BSC

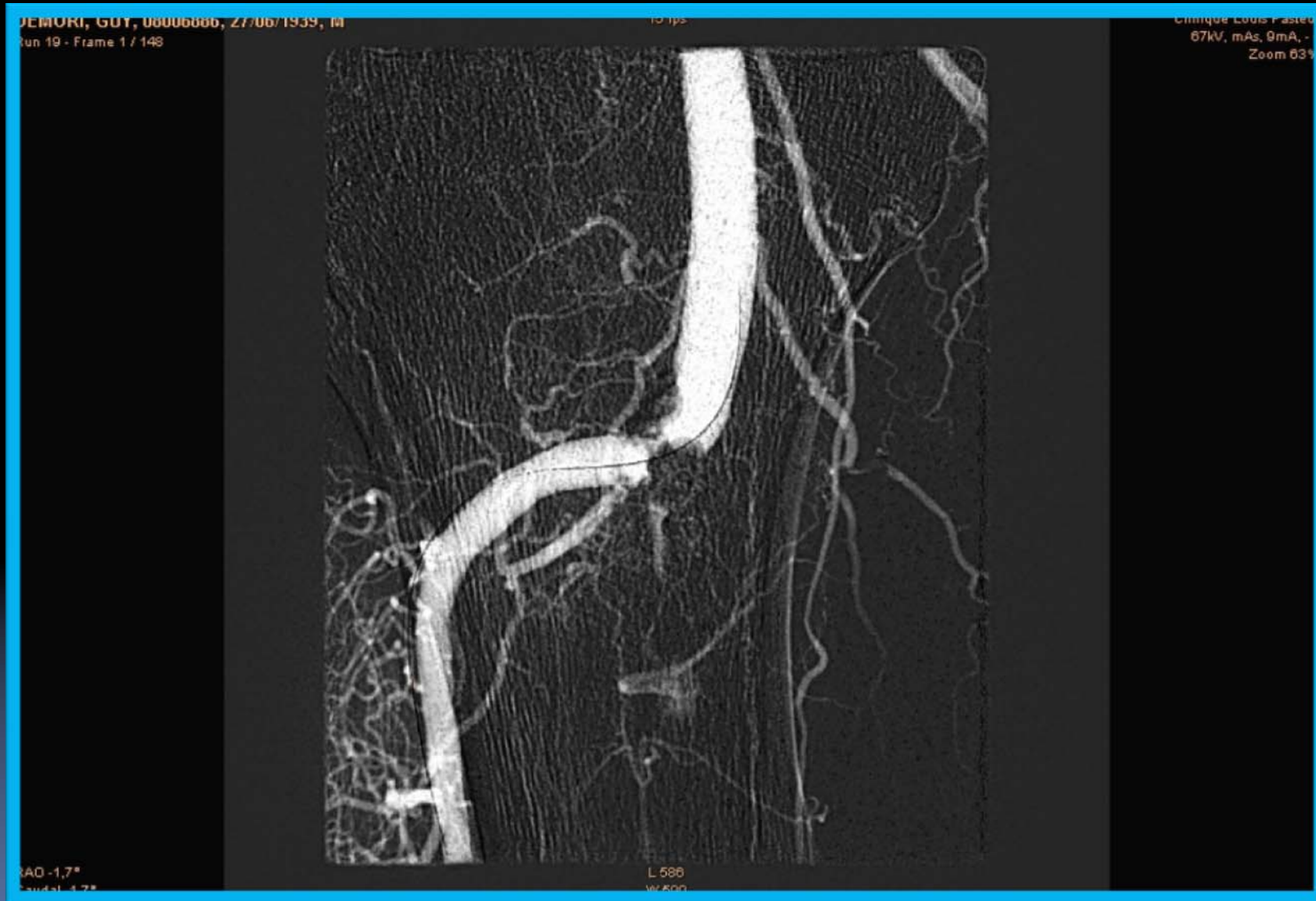2.5-10mm



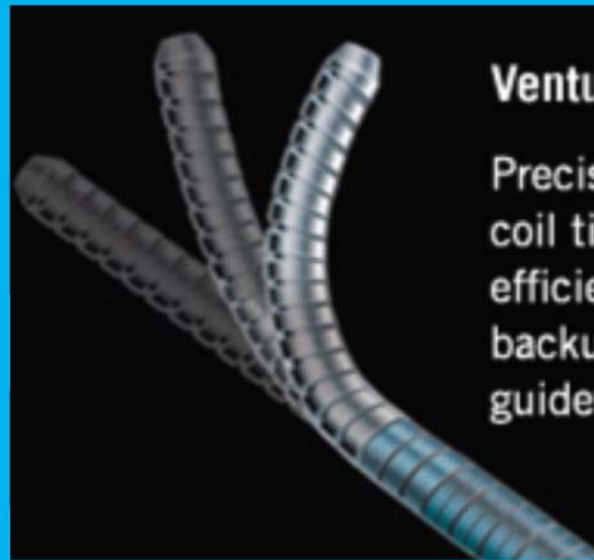

# Result after anterior tibial dilatation



# Placement of a second GW using a Venture™



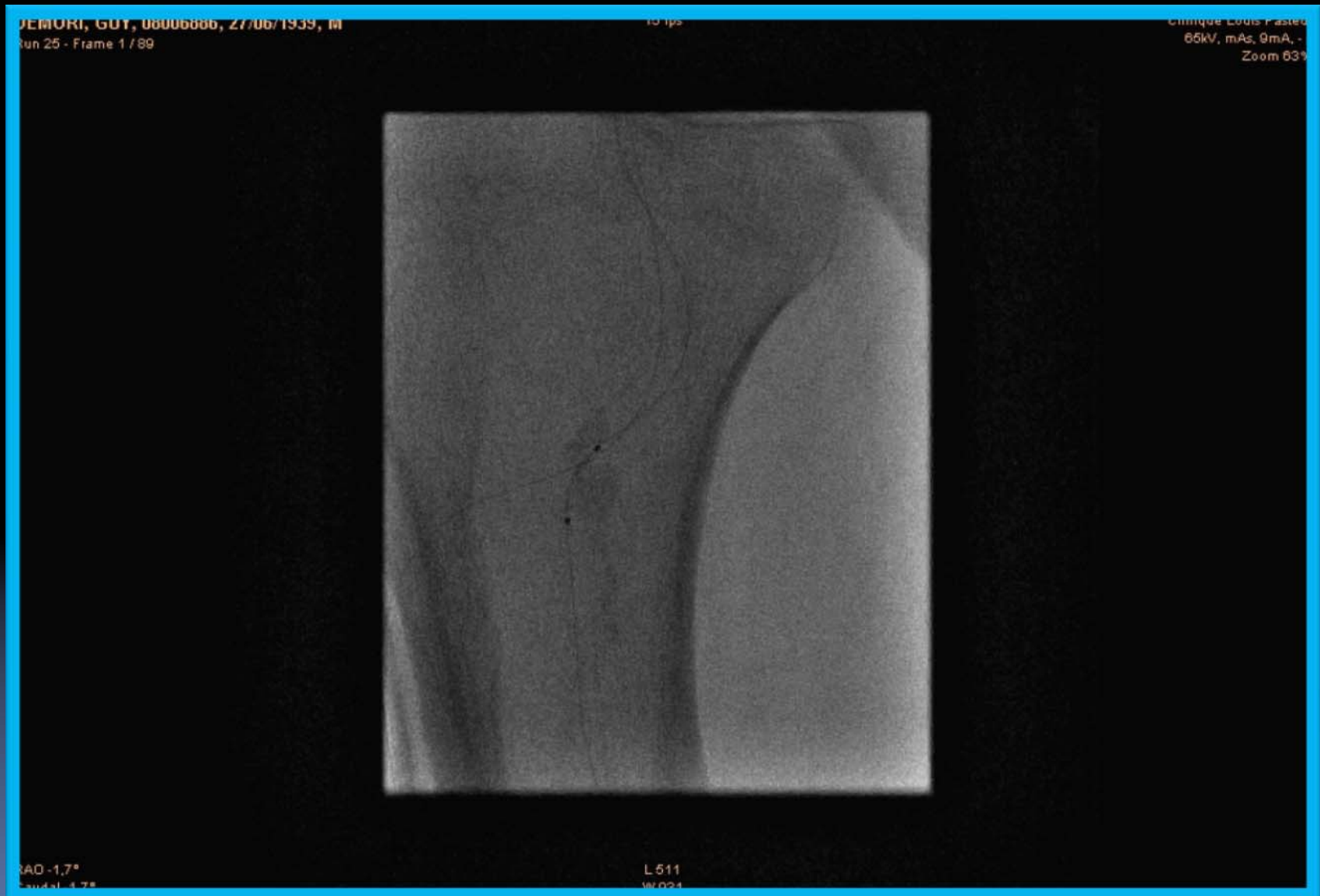# Venture wire control catheter Saint Jude



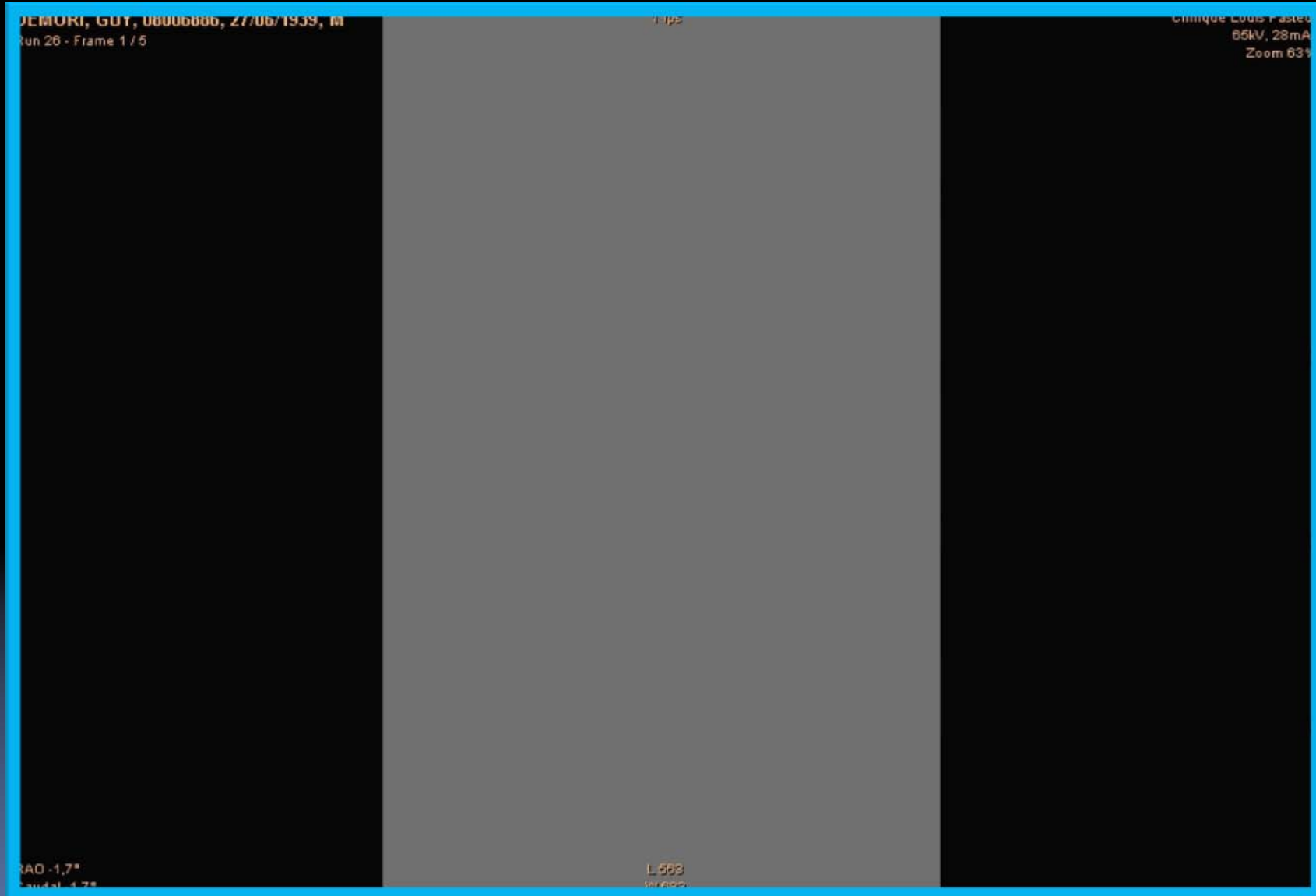
## Venture Wire Control Catheter

Precise control for difficult access. The coil tip deflects up to 90 degrees for efficient wire placement. Venture provides backup support to precisely direct the guidewire in the vessel.

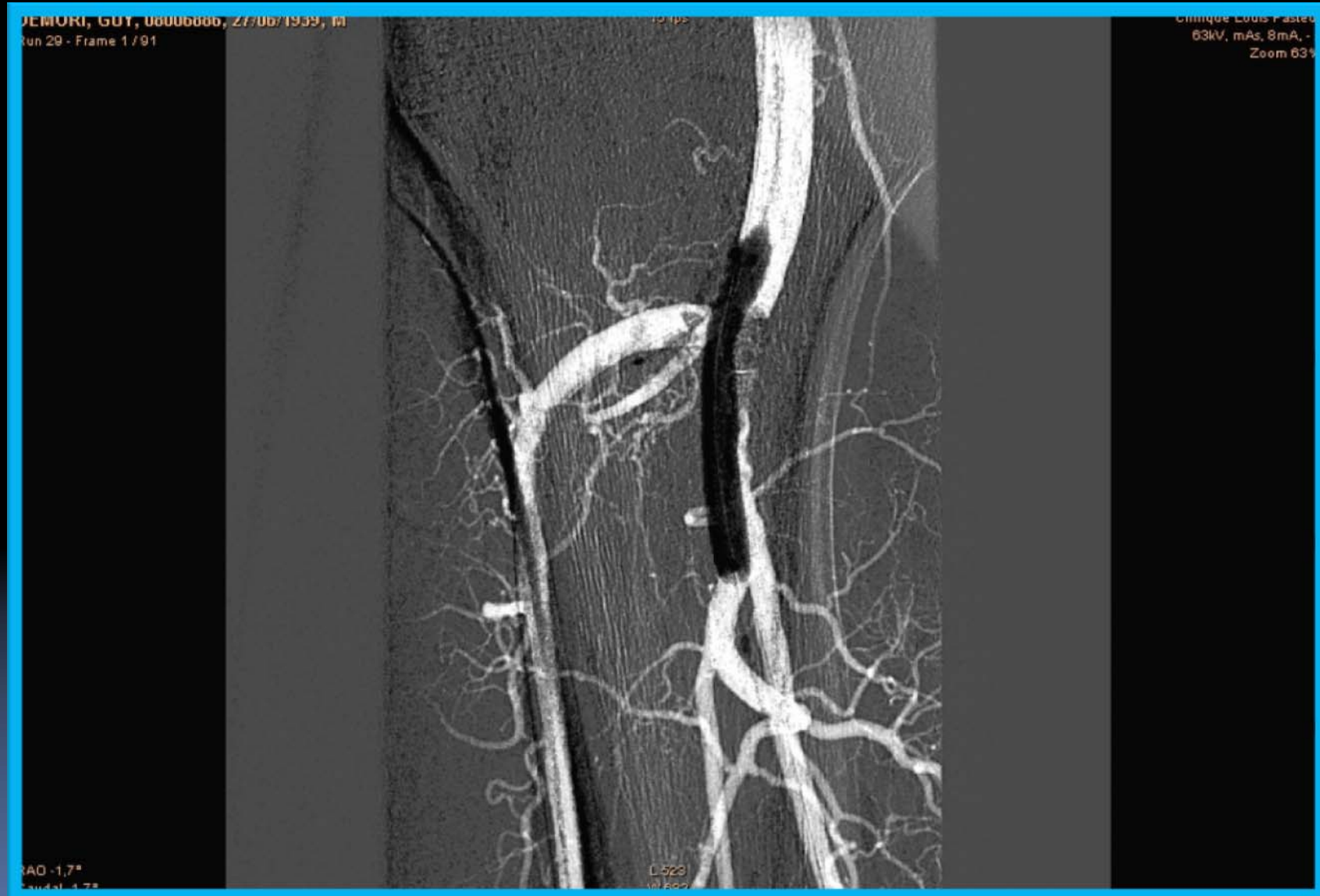# Dilatation of the tibio-peroneal



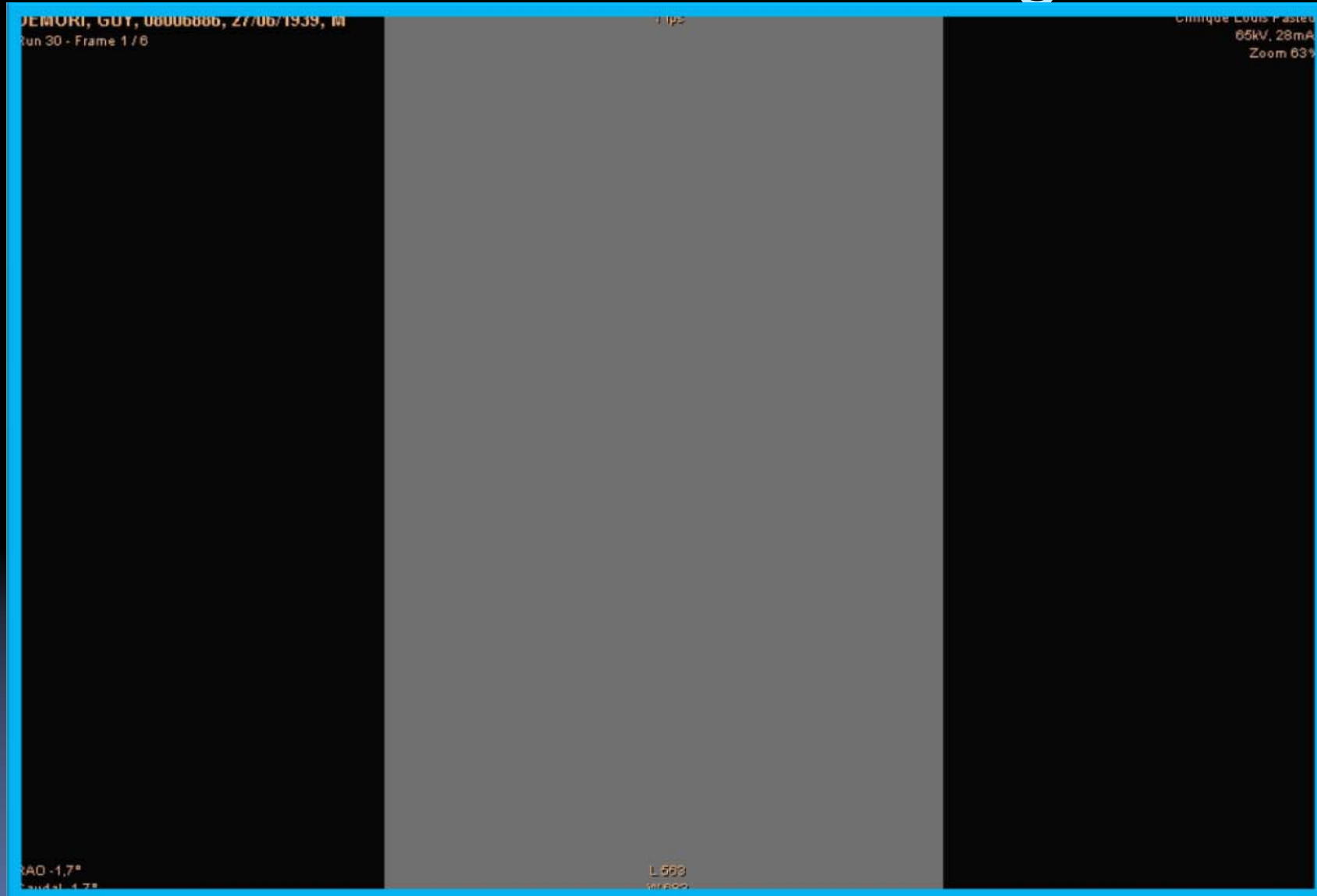
# Result after dilatation



# Kissing technique: 2,5mmx20mm , 3 x30mm

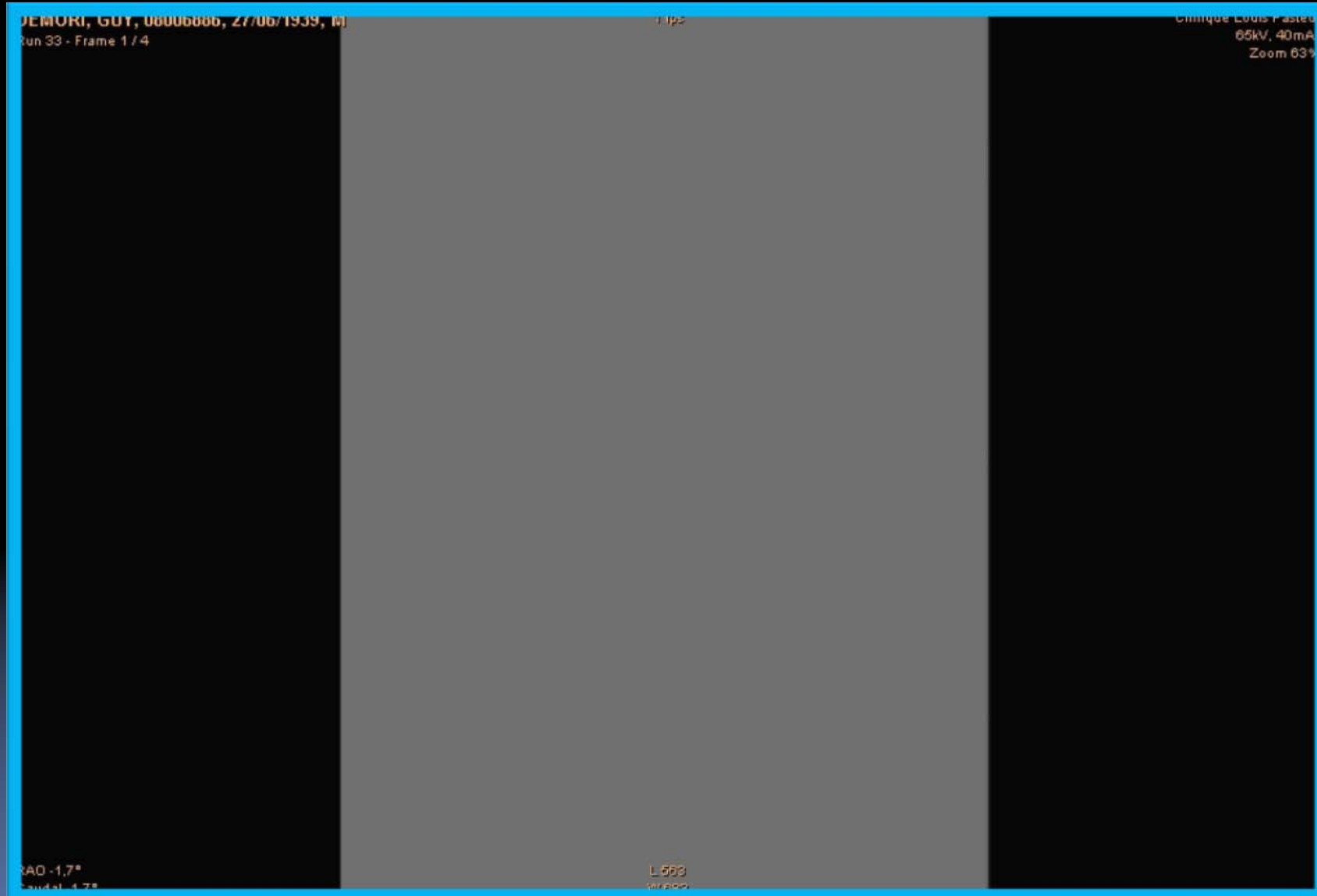


# Result after first kissing

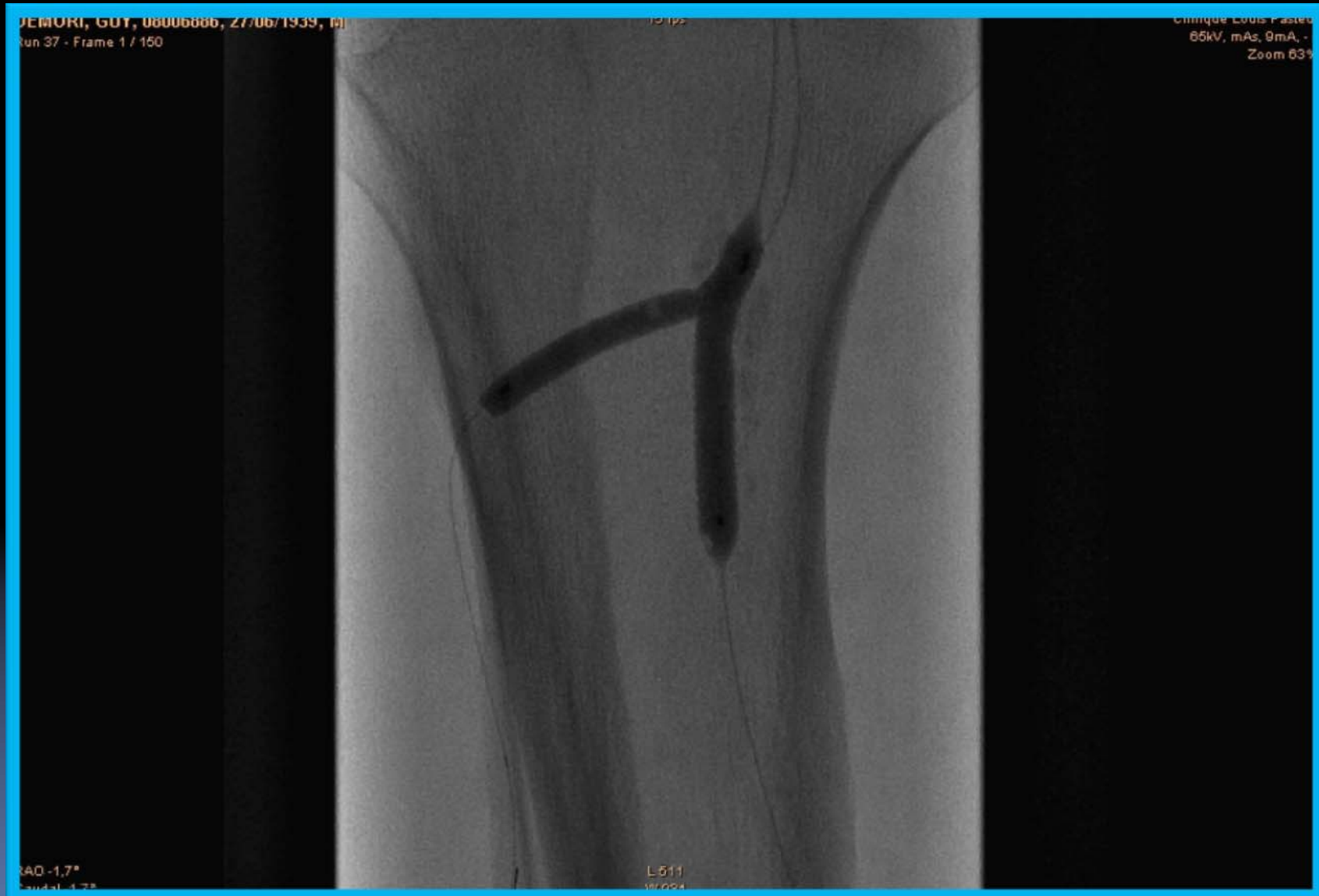



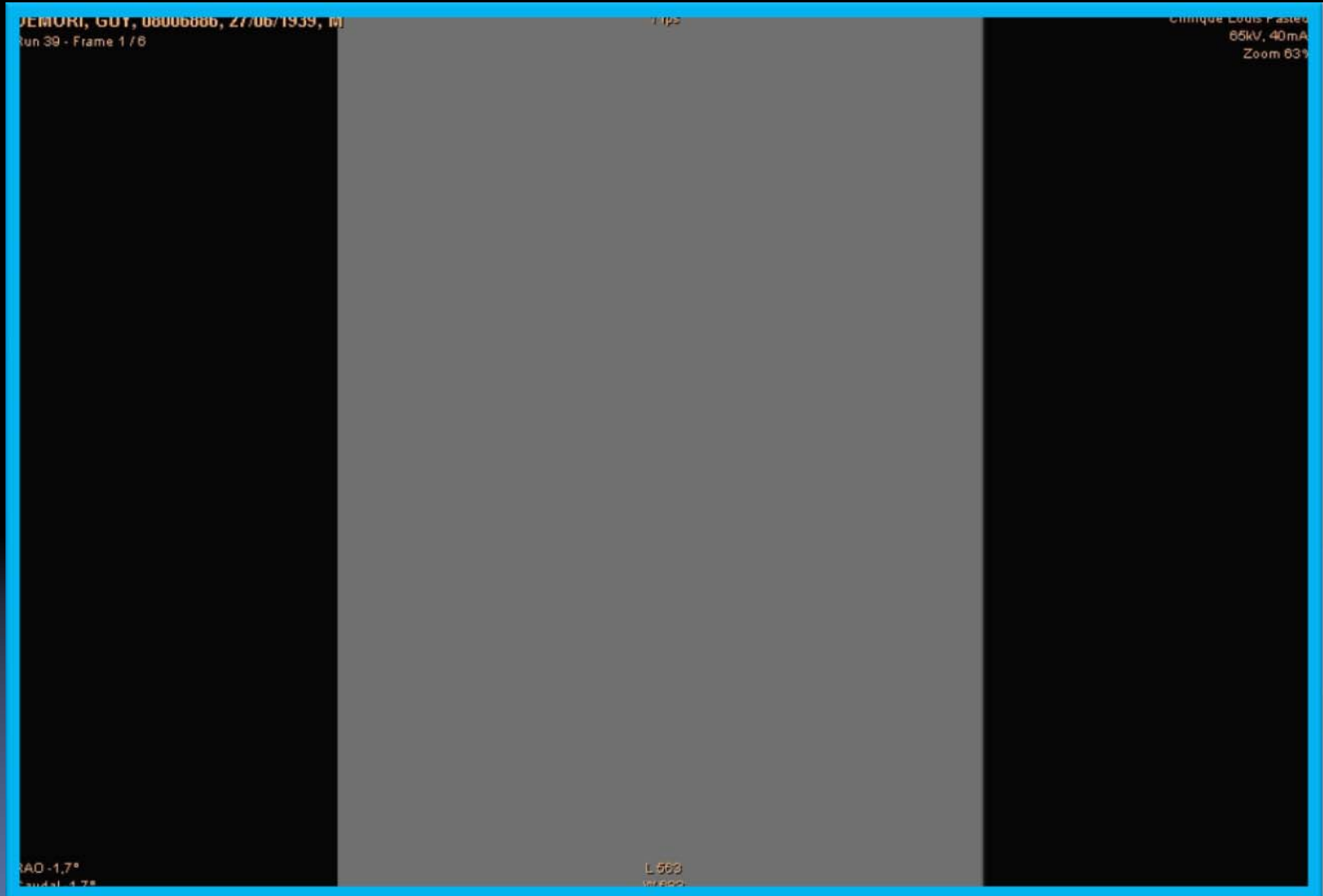
# Result after kissing with larger balloons



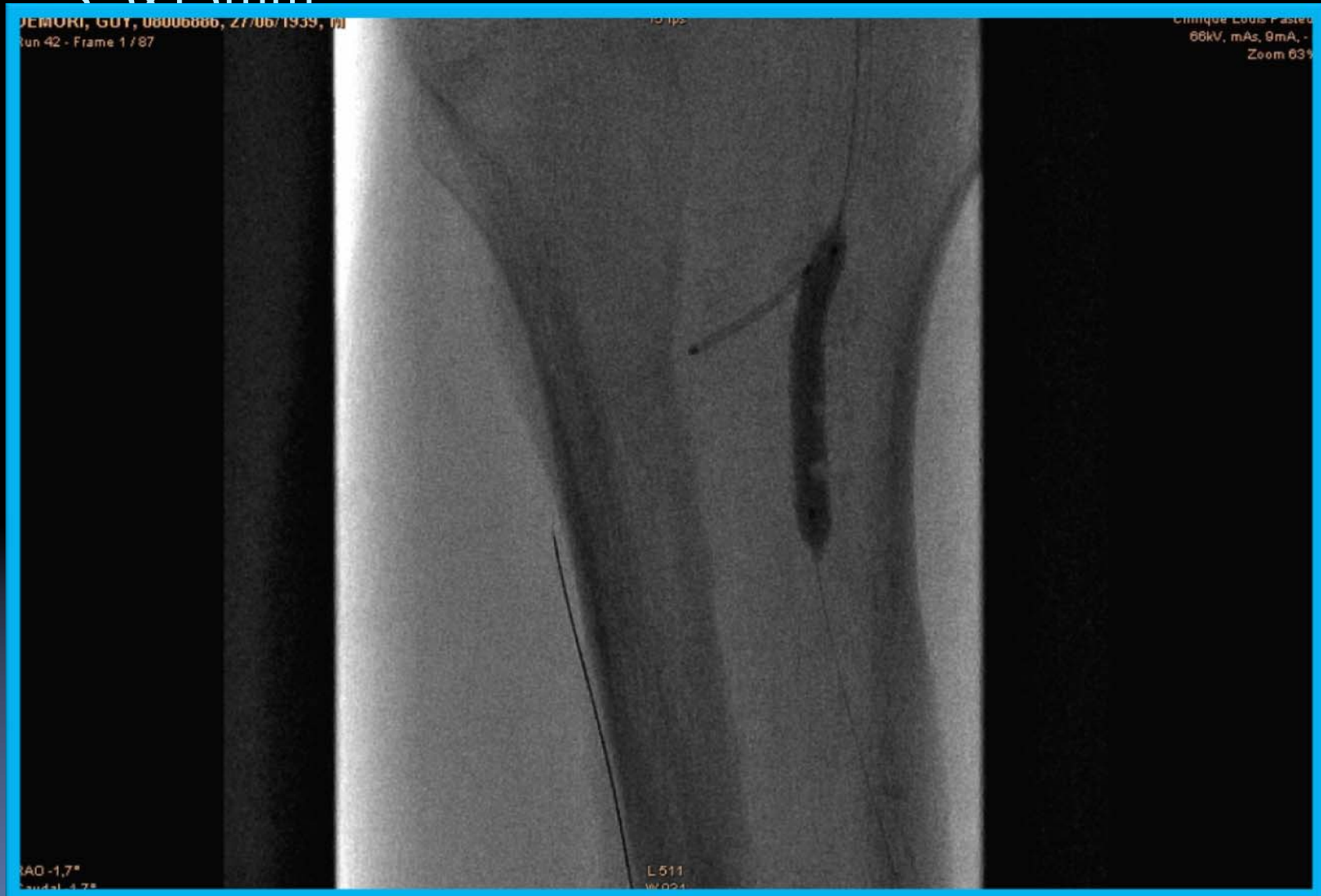# Asymmetrical stenting :TPT Promus 4 x28mm



# Result after first DES Promus BSC



# Placement of a second DES PROMUS™ BSC 3.5x15mm



# Final Result after placement of 2 Promus™

